

9 cm 8 cm 7 cm 6 cm 5 cm 4 cm 3 cm 2 cm 1 cm

TM distance
> 7.5 cm

TM
6 – 7.5 cm

TM, Thyro-mental distance
Thyroid cart. to Mentis < 6 cm (Warning)

Mouth opening (MO) > 4 cm
Inter incisive distance

MO
3–4 cm

MO < 3 cm
(Warning)

Neck extension: > 30°

10° – 30°

< 10°

Upper-Lip-Bite-Test: **Grade I (yes)**

Grade II (yes)

Grade III (yes)

Grade III (no)

Instruments: Direct Laryngoscopy

Videolaryngoscopy

Intubation Fiberscope
and/or BONFILS

Mallampati

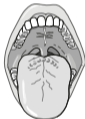Grade I – IV

At grades III – IV, 50 % are difficult to intubate

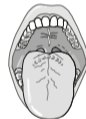Grade I



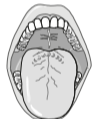Grade II



Grade III



Grade IV

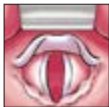


Cormack & Lehane

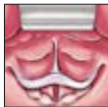
Grade I – IV

At grades III – IV it is difficult or impossible to intubate

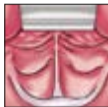Grade I



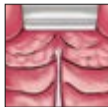Grade II



Grade III

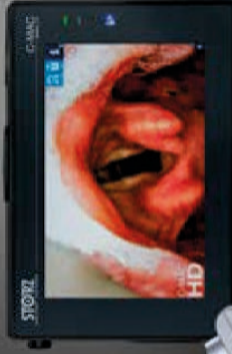

Grade IV



What was difficult last time? If the patient once had a difficult airway, the risk is high that this will happen again.

Experience True HD in
Video Laryngoscopy



C-MAC® HD

CHOICE CHANGES EVERYTHING



STORZ

KARL STORZ — ENDOSKOPE

THE DIAMOND STANDARD