Endo Press®

VIDEO-ASSISTED ANAL FISTULA TREATMENT (VAAFT)

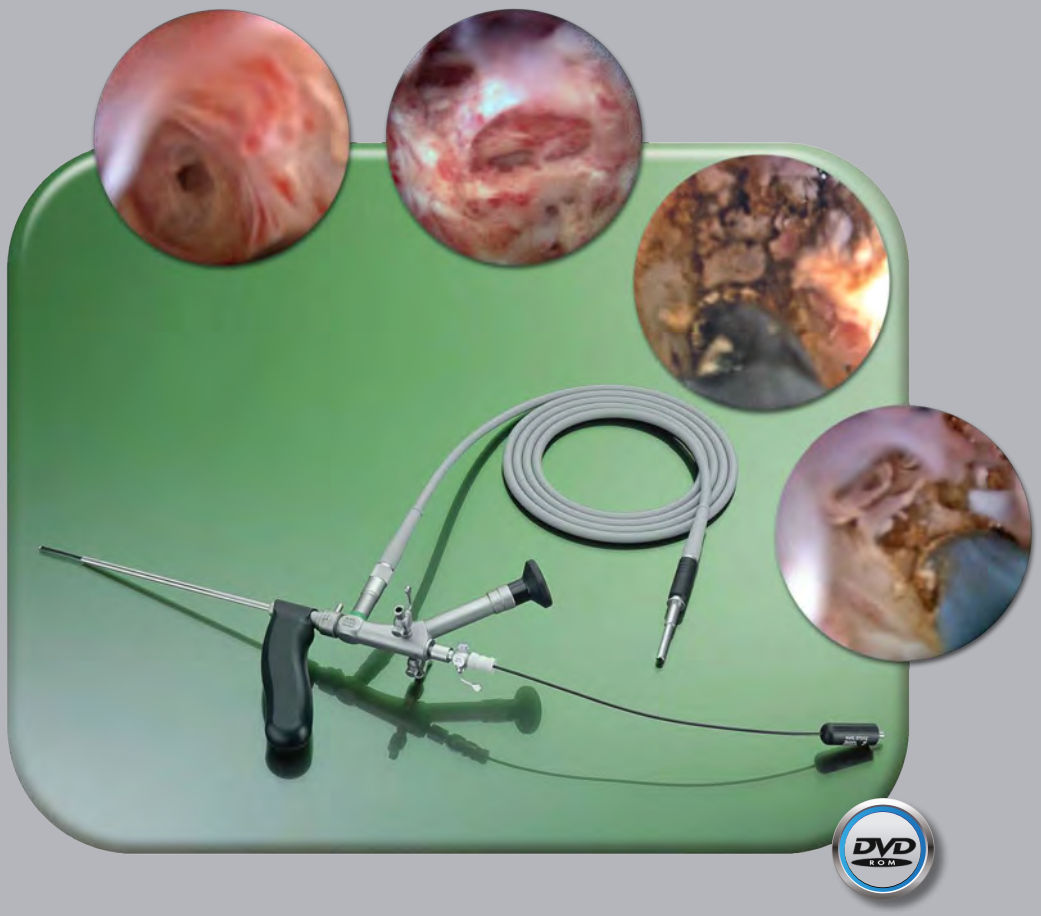

Pradeep CHOWBEY
Rajesh KHULLAR, Anil SHARMA
Vandana SONI, Manish BAIJAL

Left to right: Dr. Anil Sharma, Dr. Vandana Soni, Dr. Pradeep Chowbey (Director), Dr. Rajesh Khullar, Dr. Manish Baijal.

MAX HEALTHCARE

Institute of Minimal Access Metabolic & Bariatric Surgery

The Max Institute of Minimal Access, Metabolic and Bariatric Surgery (MAMBS), the first of its kind in the Asia Pacific subcontinent, has been expanding the horizons of Minimal Access Surgery for over two decades. The institute has been awarded the special title 'Founder' and accredited as an International Centre of Excellence for Bariatric Surgery and Hernia Surgery by the Surgical Review Corporation (SRC), USA. All Consultants at the institute have been accredited as Surgeons of Excellence by SRC.

The institute is equipped with state-of-the-art technology and infrastructure to provide quality services in Minimal Access, Metabolic and Bariatric Surgery. Academics and training programmes are one of the foremost priorities at the institute.

Address for correspondence:

Dr. Anil Sharma MS (Bom), FICS, FRCS (Edin)

Max Institute of Minimal Access, Metabolic and Bariatric Surgery

Max Super Specialty Hospital – East Block 2,

Press Enclave Road, Saket, New Delhi – 110017 (India)

Phone (off): +91-9999668200 / 9999662870 0, Fax: +91-11-66115585

E-mail: asharma736@yahoo.in / anil.sharma@maxhealthcare.com

Web: www.maxhealthcare.com

Endo : Press®

VIDEO-ASSISTED ANAL FISTULA TREATMENT (VAAFT)

Pradeep CHOWBEY,
Director

Rajesh KHULLAR
Consultant

Anil SHARMA
Consultant

Vandana SONI
Consultant

Manish BAIJAL
Consultant

Max Institute of Minimal Access, Metabolic and Bariatric Surgery
Max Super Specialty Hospital, New Delhi, India

Preface

It is a great pleasure for me to introduce this manual on the VAAFT technique, edited by Prof. Pradeep Chowbey, with whom I share a both cordial and professional relationship.

Fortunately, in the last few years, a variety of minimally-invasive techniques have been proposed in order to further improve the outcomes of surgery in the field of complex anal fistulas. Nowadays, less and less invasive techniques are employed to cure complex anal fistulas and recurrences, with increasingly widespread use of anal sphincter-saving techniques as method of first choice.

The main benefit that Video-Assisted Anal Fistula Treatment (VAAFT) possesses over the other techniques, is the direct vision. We all know that, even recently, many papers have been published about traditional techniques like lay open, seton placement, fistulectomy, etc., reporting on 30% of flatus incontinence, 4–5% soft stools and even solid stools, and that some patients are obliged to use a pad.

This is the right occasion to remember our patients suffering from anal fistulas. They are entrusted in our care and deserve to be treated as if they were our own children. Which technique would we want to be performed on them? Would we really want to run the risk of any kind of incontinence?

This fundamental idea was immediately understood by Professor Pradeep Chowbey and his staff. I met him for the first time in Santa Margherita Ligure, Italy, on the occasion of one of our international VAAFT courses, and straightaway, we both understood the importance of our mutual cooperation.

In 2011, I had the special honour to inaugurate Professor Chowbey's prestigious Department of Proctology at the Max Institute, New Delhi. I have personally witnessed his high level of professionalism and advanced skills, not only in the field of bariatric surgery, but also in other surgical specialties.

In order to provide evidence, it is sufficient to read this manual and one will realize the true dimension of the outstanding work of Prof. Chowbey and his staff.

I also want to express my cordial gratitude to him and his staff for spreading the VAAFT technique all over India while taking care of their patients in the best possible way.

Sincere thanks also go to the members of Prof. Chowbey's staff, Dr Sharma, Dr Soni, Dr Khullar and Dr Baijal. All our staff congratulates them for their valuable work and I personally wish them every future success.

Prof. Piercarlo Meinero

Acknowledgement

Grateful acknowledgement to Dr. *Khoobsurat Najma,* Medical Writer at Max Institute of Minimal Access, Metabolic and Bariatric Surgery, for conceptualizing, compiling and editing the scientific content of this manuscript.

The authors are thankful to Ms. *Tripta Sharma,* Mr. *Anshul Chauhan,* Mr *Pankaj Gupta* and Ms. *Aenu Batra* for technical assistance and secretarial support.

Please note:

Attached to the inside back cover is a DVD **KS 774** titled **"Video-Assisted Anal Fistula Treatment (VAAFT)"**, produced by *Prof. Pradeep Chowbey and collaborators*.

Important notes:

Medical knowledge is ever changing. As new research and clinical experience broaden our knowledge, changes in treatment and therapy may be required. The authors and editors of the material herein have consulted sources believed to be reliable in their efforts to provide information that is complete and in accord with the standards accepted at the time of publication. However, in view of the possibility of human error by the authors, editors, or publisher, or changes in medical knowledge, neither the authors, editors, publisher, nor any other party who has been involved in the preparation of this booklet, warrants that the information contained herein is in every respect accurate or complete, and they are not responsible for any errors or omissions or for the results obtained from use of such information. The information contained within this booklet is intended for use by doctors and other health care professionals. This material is not intended for use as a basis for treatment decisions, and is not a substitute for professional consultation and/or use of peer-reviewed medical literature.

Some of the product names, patents, and registered designs referred to in this booklet are in fact registered trademarks or proprietary names even though specific reference to this fact is not always made in the text. Therefore, the appearance of a name without designation as proprietary is not to be construed as a representation by the publisher that it is in the public domain.

The use of this booklet as well as any implementation of the information contained within explicitly takes place at the reader's own risk. No liability shall be accepted and no guarantee is given for the work neither from the publisher or the editor nor from the author or any other party who has been involved in the preparation of this work. This particularly applies to the content, the timeliness, the correctness, the completeness as well as to the quality. Printing errors and omissions cannot be completely excluded. The publisher as well as the author or other copyright holders of this work disclaim any liability, particularly for any damages arising out of or associated with the use of the medical procedures mentioned within this booklet.

Any legal claims or claims for damages are excluded.

In case any references are made in this booklet to any 3rd party publication(s) or links to any 3rd party websites are mentioned, it is made clear that neither the publisher nor the author or other copyright holders of this booklet endorse in any way the content of said publication(s) and/or web sites referred to or linked from this booklet and do not assume any form of liability for any factual inaccuracies or breaches of law which may occur therein. Thus, no liability shall be accepted for content within the 3rd party publication(s) or 3rd party websites and no guarantee is given for any other work or any other websites at all.

Video-Assisted Anal Fistula Treatment (VAAFT)

Pradeep Chowbey, Director,
Rajesh Khullar, Consultant,
Anil Sharma, Consultant,
Vandana Soni, Consultant,
Manish Baijal, Consultant

Max Institute of Minimal Access, Metabolic and Bariatric Surgery, Max Super Specialty Hospital, New Delhi, India

Correspondence address of the author:

Dr. Anil Sharma, MS (Bom), FICS, FRCS (Edin)
Max Institute of Minimal Access, Metabolic and Bariatric Surgery, Max Super Specialty Hospital – East Block 2, Press Enclave Road, Saket, New Delhi – 110017, India
Phone (off): +91-9999668200/9999668700
Fax: +91-11-66115585
E-mail: asharma736@yahoo.in
anil.sharma@maxhealthcare.com
Web: www.maxhealthcare.com

All rights reserved.
1st edition 2013
© 2015 Endo:Press® GmbH
P.O. Box, 78503 Tuttlingen, Germany
Phone: +49 (0) 74 61/1 45 90
Fax: +49 (0) 74 61/708-529
E-Mail: endopress@t-online.de

No part of this publication may be translated, reprinted or reproduced, transmitted in any form or by any means, electronic or mechanical, now known or hereafter invented, including photocopying and recording, or utilized in any information storage or retrieval system without the prior written permission of the copyright holder.

Editions in languages other than English and German are in preparation. For up-to-date information, please contact Endo:Press® GmbH at the address shown above.

Design and Composing:
Endo:Press® GmbH, Germany

Printing and Binding:
Straub Druck + Medien AG
Max-Planck-Straße 17, 78713 Schramberg, Germany

1.0 07.15-0.5

ISBN 978-3-89756-955-3

Table of Contents

Classification of Anal Fistulae 8

Patient Selection 9
- **Indications** 9
- **Contraindications** 9

Equipment 9
- **Fistuloscope** 10
- **Video Equipment** 10

Operating Technique 10
- **Operating Room Setup and Patient Positioning** 10
- **Preparation and Assembly of Instruments** 10
- **Initial Diagnostic Assessment** 11

Surgical Procedure 11
- **Localization of the Internal Opening** 12
- **Examination and Fulguration of the Fistula Track** 14
- **Closure of the Internal Opening** 16

Postoperative Care 17

Discussion 17

References 18

VAAFT Instrument Set for Video-Assisted Anal Fistula Treatment
IMAGE1 S Camera System and Accessories 20

Introduction

An anal fistula is defined as a track lined with granulation tissue. The track connects a primary opening inside the anal canal to a secondary opening in the perianal skin. The overall prevalence of anal fistula is 8–10 cases per 100,000 individuals with a male: female ratio of 2:1. Anal fistula can have a primary etiology, resulting from an anorectal abscess or can develop secondary to trauma, tuberculosis, Crohn's disease, anal fissures, certain infections (actinomycosis, chlamydia, HIV), carcinomas and exposure to radiation. Anorectal abscess can be complicated by anal fistula in about 25% of patients during the acute phase of sepsis or within 6 months thereafter.

Among the treatment options available for anal fistulae, there are both traditional and novel techniques. The traditional methods include fistulotomy (laying open of the track) and fistulectomy (excision of the entire track) for low fistulae. For high and complex fistulae, seton placement is traditionally the preferred treatment modality used to minimize incontinence. More complex surgical procedures in the form of local advancement flaps have met with moderate success. The newer treatment options include use of fibrin glue, bio-prosthetic plugs and ligation of intersphincteric fistula tract (LIFT). Traditional techniques including fistulectomy and use of cutting seton have been associated with incontinence, especially in patients who have had previous surgery[4]. Mucosal advancement flaps are technically challenging and are found to have high rates of recurrence and postoperative incontinence.[1, 8, 9, 11, 14, 16]. The LIFT procedure has proved to be associated with good healing rates.[2, 12, 13, 15]

In recent years, a minimally invasive video-assisted technique has emerged using a specially designed fistuloscope.[6] The **V**ideo-**A**ssisted **A**nal **F**istula **T**reatment (VAAFT) was developed by Professor *P. Meinero* in 2006.[6] The technique involves the identification and secure internal closure of the internal fistula opening and visualization with cauterization of the fistulous track using a specially designed fistuloscope. We adopted the technique in April 2011 in an effort to reduce postoperative morbidity and to enable our patients to benefit from the advantages of minimally invasive surgery. Between April 2011 and December 2012, VAAFT was performed in 416 patients at our Division of Proctology at the Max Institute of Minimal Access, Metabolic and Bariatric Surgery, New Delhi, India. The brochure reflects our experience with the new technique over this period.

Classification of Anal Fistulae

Various classifications for anal fistulae have been proposed over several decades. *Milligan* and *Morgan,* in 1934, classified anal fistulae on the basis of the relation of the fistulous track to the anorectal ring.[7] They were subdivided into anal and anorectal fistulae, depending on the location below or above the level of the anorectal ring. *Stelzner,* in 1959, classified anal fistulae into three main types: intermuscular, transsphincteric and extrasphincteric, in relation to the external anal sphincter.[17] *Goligher* modified the classification of *Milligan* and *Morgan* by subdividing high anorectal fistulae into ischiorectal or infralevator and pelvirectal or supralevator.[3] *Thompson* classified anal fistulae on the basis of frequency and ease of operation into simple and complex anal fistulae.[18] *Lilius*, in 1968, classified anal fistulae as seen during the operative procedure into: subcutaneous, low intermuscular, high intermuscular, low anal, high anal and pelvirectal.[5]

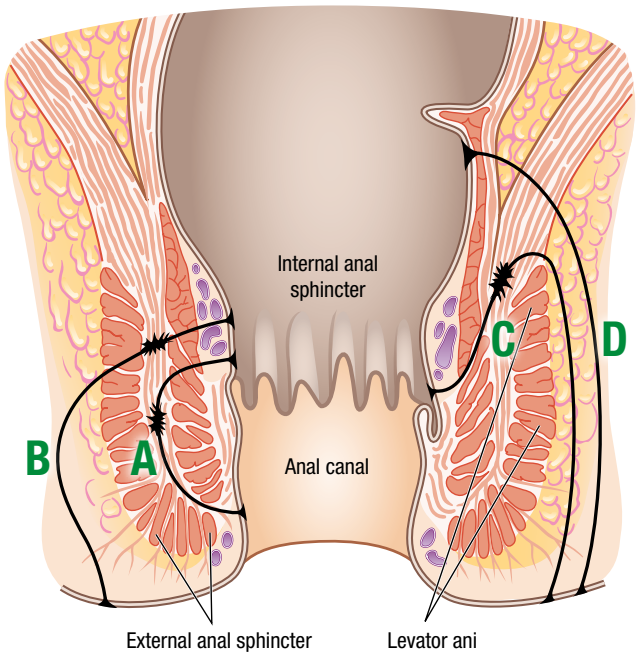

1 Classification of anal fistulae according to *Parks*.[10] Intersphincteric (**A**), Transsphincteric (**B**), Suprasphincteric (**C**), Extrasphincteric (**D**).

The most widely used classification for anal fistulae was formulated by *Parks* in 1976.[10] The Parks classification relates the type of fistula to the external anal sphincter / puborectalis complex. According to *Parks' classification*, anal fistulae are classified into four main types (**Fig. 1**). These include:

- Intersphinteric fistula
- Transsphincteric fistula
- Suprasphincteric fistula
- Extrasphincteric fistula

Intersphincteric fistula is the most common anal fistula which predominantly arises from an infection within an anal gland, that tracks down towards the anal margin. Here, the fistula track is mainly confined to the intersphincteric plane. A trans-sphincteric fistula connects the intersphincteric plane with the ischiorectal fossa by perforating the external sphincter muscle. A suprasphincteric fistula passes above the external sphincter muscle and perforates the levator ani. An extrasphincteric fistula passes from the rectum to the perianal skin, completely external to the sphincter apparatus.

Anal fistulae can also be clinically classified as simple and complex anal fistula. A simple anal fistula consists of a single tract that involves < 30–50% of external anal sphincters. These fistulae can be probed and the overlying skin incised and laid open for the fistula tract to heal. Complex anal fistulae may consist of multiple tracts in > 30–50% of external anal sphincters, are found in an anterior location, and may be related to an etiology of radiation exposure and inflammatory bowel disease. Complex fistulae can be found in patients with already compromised sphincter function (prone to incontinence). These complex fistulae commonly require a staged procedure wherein the first step is to control sepsis by seton placement.

Preoperative magnetic resonanace imaging (MRI), applied as an adjunct modality in diagnostic workup and treatment planning, has shown to be very useful in achieving an optimal outcome of this new surgical technique. MRI is commonly used during initial diagnostic assessment and treatment planning for:

- Identification of the primary fistulous tract as well as its secondary ramifications.
- Identification of associated abscesses.
- Identification of the type of fistula.
- Detection of inflammatory swellings or fibrosis.
- Demonstration of occult intersphincteric space sepsis.
- Assessment of long-term outcomes.

Patient Selection

Indications

All discharging fistulae, which include:

- Mature fistula.
- Medium to high fistula with well-formed single or multiple tracks.
- Complex fistula (recurrent fistula, horse shoe fistula).

Contraindications

- Submucous fistula.
- Low perianal fistula.
- Fistula with acute/recent inflammation (immature track).
- Pelvic fistula (diagnosed by MRI)
- No active discharge for at least 2 months.
- Fistula secondary to systemic pathologies (Crohn's disease, tuberculosis, actinomycosis, post irradiation, malignancy).

Equipment

Use of dedicated equipment is highly recommended (KARL STORZ Tuttlingen, Germany). The instrument set essentially comprises the following components (**Fig. 2**):

- Fistuloscope (1)
- 3-mm Forceps (2)
- Endobrush (3)
- Unipolar Electrode (4)

In addition, the surgeon will require

- Anoscope (5)
- Linear Endostapler (6)
- Glycine-mannitol 1% solution
- Volkmann Spoon (7)

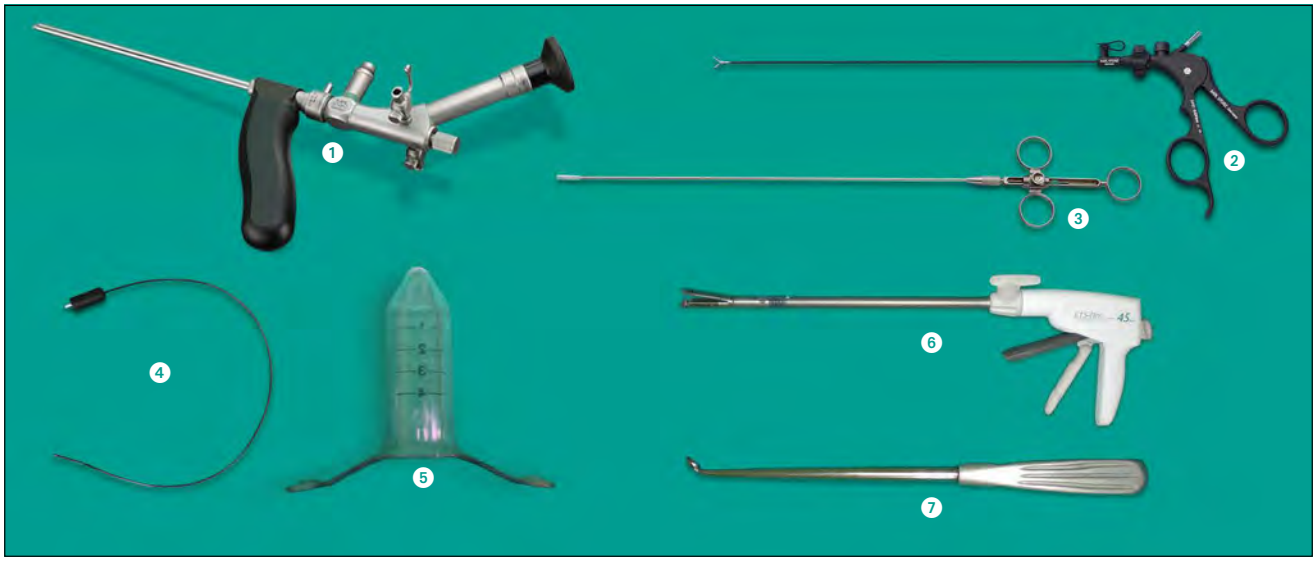

2

Fistuloscope

The fistuloscope offers an 8° direction of view and has a straight working channel also used as irrigation channel. The operative length is 18 cm and the outer diameter is 3.3 x 4.7 mm (**Fig. 3**).

Video Equipment

We use a standard high definition (HD) technology for our video equipment (**Fig. 4**). (IMAGE1™ HD, KARL STORZ Tuttlingen, Germany). These endoscopic camera systems are equipped with three CCD chips that support the 16: 9 input format and capture images with a resolution of 1920 x 1080 pixels (**Fig. 5**).



3 Fistuloscope (KARL STORZ Tuttlingen, Germany).

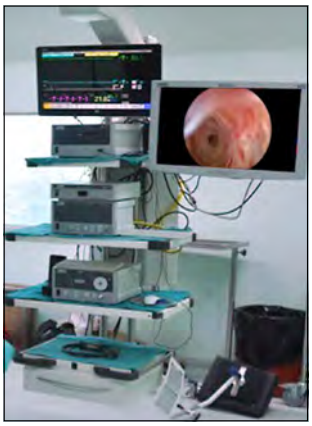

4 Video equipment in the OR.

5 High-definition video camera.

Operating Technique

Operating Room Setup and Patient Positioning

The patient is placed in a lithotomy position with 15°–20° Trendelenburg tilt, as shown in **Fig. 6**. The procedure is performed under spinal/general anesthesia.

Preparation and Assembly of Instruments

Once the presence of a subcutaneous fistula has been excluded, a decision to proceed with VAAFT is taken. The fistuloscope is connected to the cold light source and loaded with the obturator. The irrigation tubing which is connected to a bag containing Glycine-Mannitol 1% solution, is attached to the LUER inlet of the fistuloscope (**Fig. 7**).

6 Patient positioning and operating room setup.

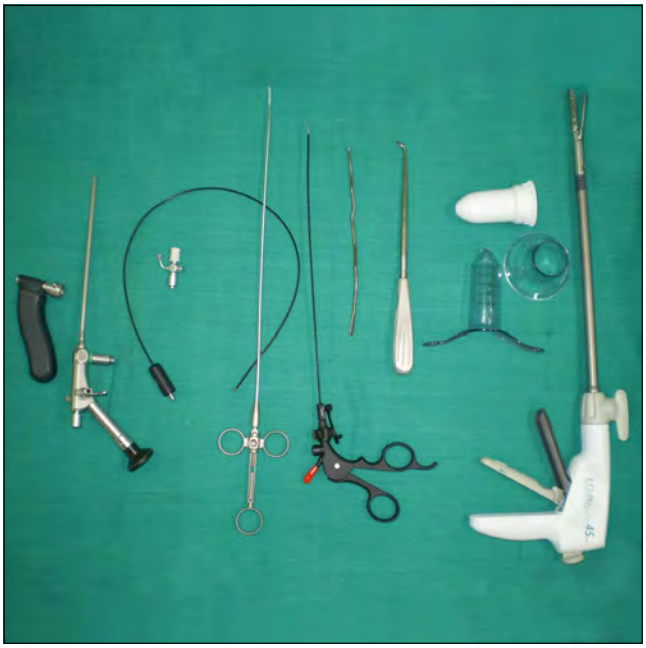

7 Instrument set for Video-Assisted Anal Fistula Treatment (VAAFT).

Initial Diagnostic Assessment

The initial diagnostic assessment involves examination of perianal area and the perineum for external fistula openings (**Fig. 8**). Digital per rectal examination and proctoscopy is performed to assess anorectal pathology and to localize the site of the internal opening of the fistula.

8 Opening of external fistula.

Surgical Procedure

The external opening of the fistula is dilated with the tip of a fistula probe, if required (**Fig. 9**). Fibrous scar tissue is excised to enlarge the opening in order to allow entry of the fistuloscope (**Fig. 10**). Prior to inserting the fistuloscope, the tip is placed just within the external opening and the LUER stopcock is opened allowing the glycine-mannitol 1% solution to distend and delineate the fistula track (**Fig. 11**).

9 Initial dilation of the external fistula opening.

10 Fibrous scar tissue is excised to enlarge the external fistula opening.

11 The fistuloscope is inserted through the external fistula opening.

Localization of the Internal Opening

The fistuloscope is gently advanced through the fistula tract which is distended by the irrigation solution (**Fig. 12**). The fistuloscope is slowly advanced with side-to-side, rotatory or vertical movements as may be required. The operative maneuvers are guided on the basis of the real-time image on the video monitor located at the head end of the patient. A typical fistula tract appears as a tunnel with granulation tissue and fibrous tissue in the form of whitish flakes appearing within the fistula tract (**Figs. 13a–c**). At this stage, an attempt is made to locate the position of the internal fistula opening. An anal retractor is inserted to localize the position of the internal opening. In many instances, a jet of irrigating solution is seen spurting from the internal opening from within the anal canal (**Fig. 14**). In some patients with a well-defined fistula tract and large internal opening, the fistuloscope itself may exit through the internal opening into the anal canal. In other patients, the internal opening may be obliterated or concealed within a fold of mucosa. In these patients, the transillumination effect of the

12 The fistuloscope is advanced while distending the fistula track with irrigation solution.

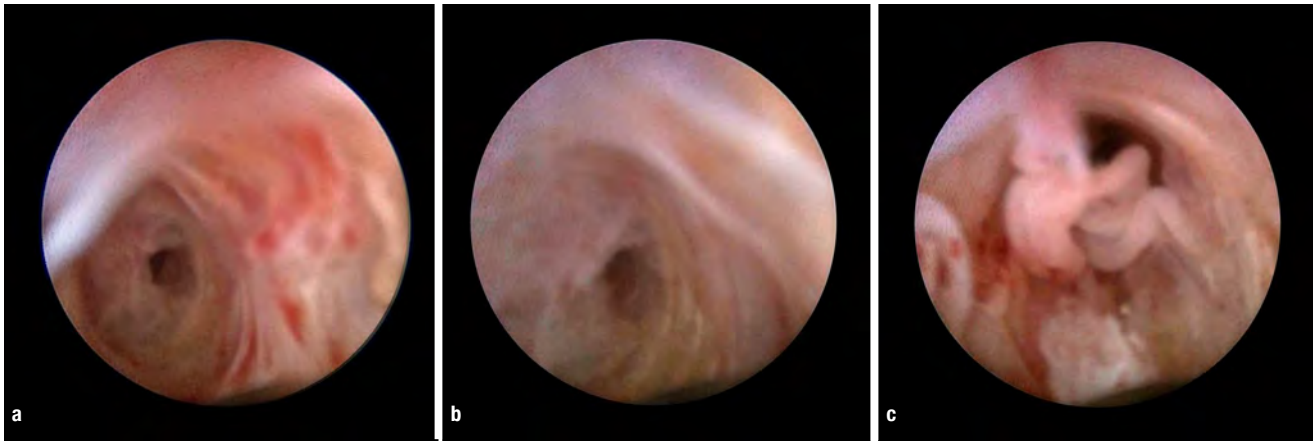

13 Endoscopic aspects of the fistula track (**a, b**). Fistula track with fibrous tissue (**c**).

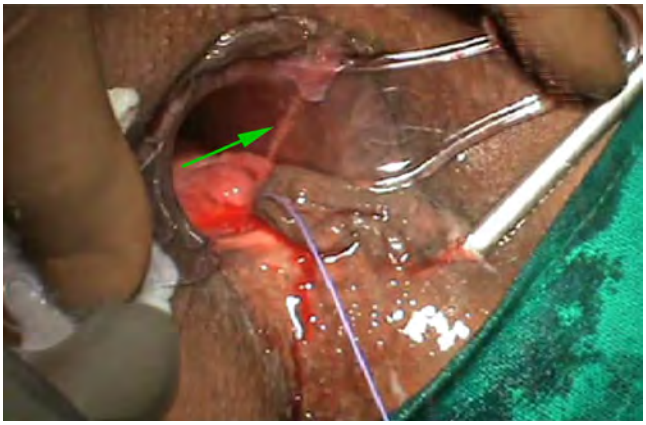

14 Jet of irrigation fluid spurting from the internal opening.

light of the fistuloscope shining through the bowel wall (with the lights of the OR switched off) may provide a clue to the location of the internal opening (**Fig. 15**). Provided, the internal opening cannot be identified, no attempt should be made to create an artificial internal opening.

Once the internal opening of the fistula has been localized on the bowel wall, it is isolated and marked with 3 stay sutures. The sutures are placed through the full thickness of the rectal mucosa (**Figs. 16–19**). The first suture is placed distal to the opening, the second at the opening and the third proximal to the internal opening. The tails of the sutures are kept long and are held by means of an artery forceps outside the anal canal.

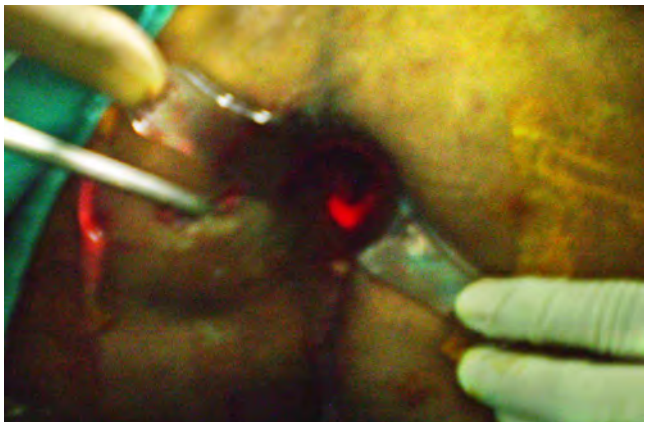

15 Transillumination effect due to the light of the fistuloscope shining through the nearby internal opening.

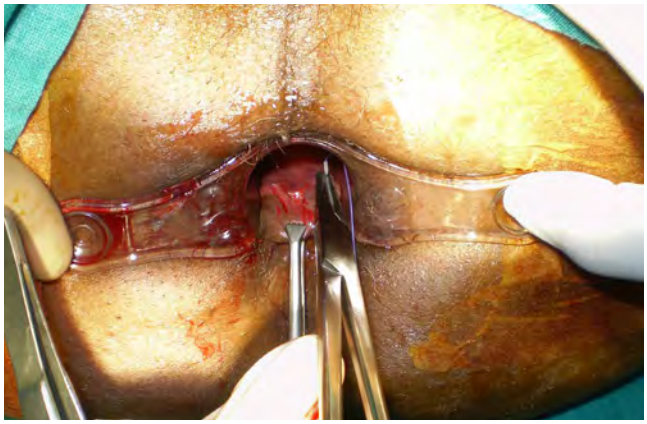

16 Stay sutures are placed through the anal mucosa to mark the internal opening.

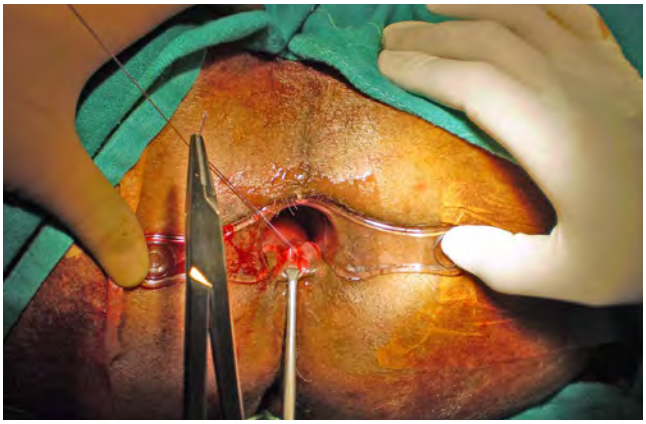

17

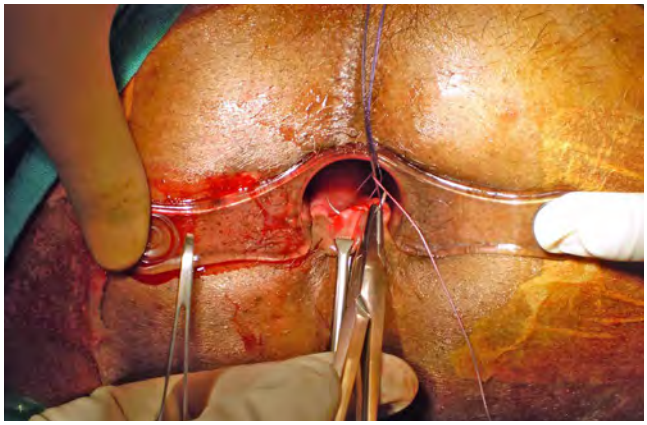

18

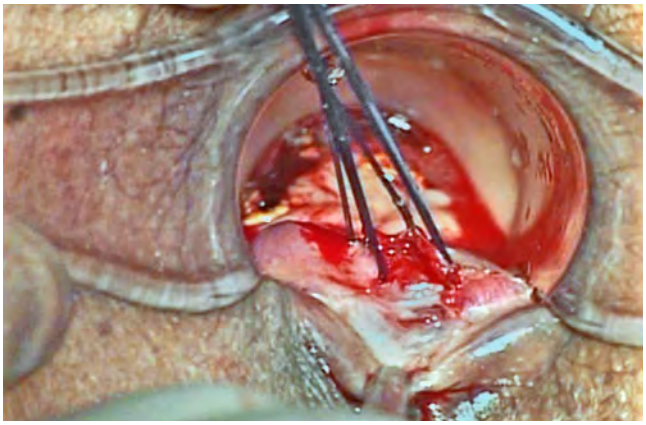

19

Examination and Fulguration of the Fistula Track

Once the internal opening has been localized and isolated with stay sutures, the entire fistula tract is examined for secondary fistulous tracks and abscess cavities. The fistulous tract is re-examined with the fistuloscope starting at the external opening. The fistuloscope is advanced to search for any secondary tracks and abscess cavities (**Figs. 20a–b**). Any abscess cavities that are identified should be drained, followed by fulguration of their walls. Secondary tracks, if present, are entered with the fistuloscope and granulation tissue on the walls is fulgurated. The entire lining of the fistula tract is fulgurated. Fulguration is carried out by means of flexible monopolar electrode that is passed through the working channel of the fistuloscope (**Figs. 20c–g**).

20 Multiple fistula tracks (**a**). Fistula tracks showing abscess cavities (**b**). Fulguration of fistula track (**c–g**).

20

20

Debridement is completed with the help of an endobrush (passed through the fistuloscope, **Figs. 21–23**) and with a Volkmann spoon (after removal of the fistuloscope, **Fig. 24**). Excised tissue is sent for histopathological examination.

21 Endobrush being introduced through the working channel of fistuloscope.

22 Endoscopic view of the endobrush's tip.

23 Debridement with an endobrush.

24 Debridement with a Volkmann spoon.

Closure of the Internal Opening

The anal retractor is re-inserted, thus affording a good view of the internal opening with stay sutures. Traction is applied on stay sutures perpendicular to the bowel wall and a linear endostapler (white cartridge) is applied at the base (**Fig. 25a**). This ensures a secure stapled closure of internal opening (**Figs. 25b, c**). The staple line is inspected for haemostasis (**Fig. 25d**). A temporary dressing is applied to the external opening.

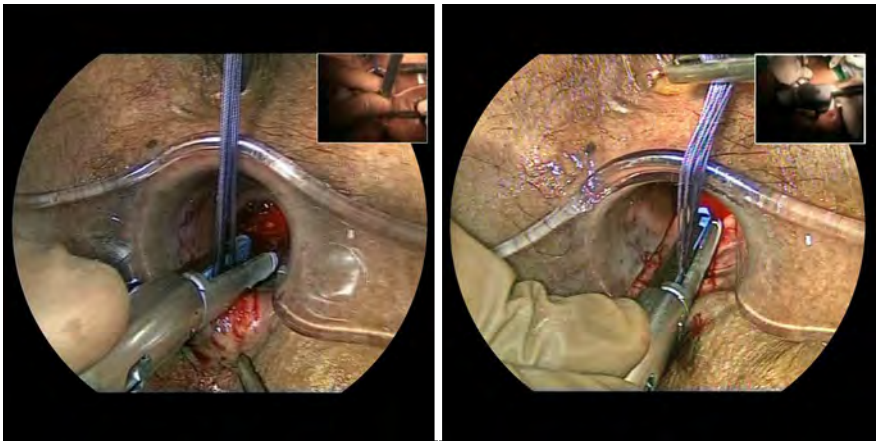

25 Preparation for stapling the anal mucosa at the site of the internal opening (**a**). The linear Endostapler is fired (**b**).

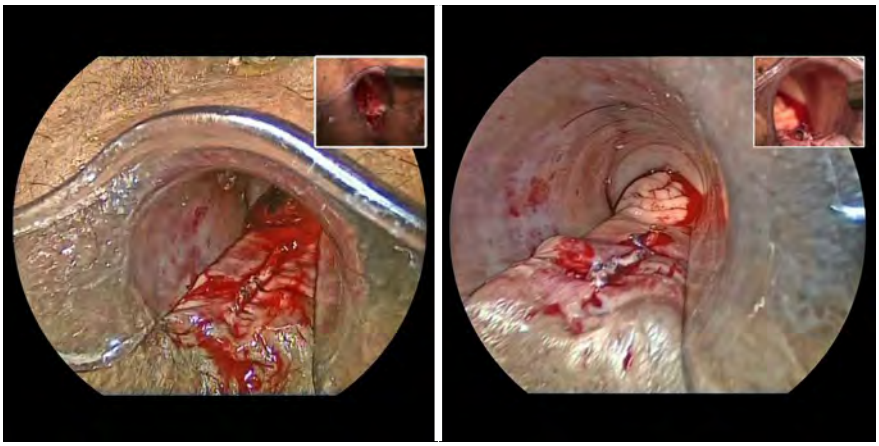

25 Stapled closure of anal mucosa at the site of the internal fistula opening (**c**). Inspection for haemostasis (**d**).

Postoperative Care

All patients are administered oral Diclofenac sodium 75mg BD for 2 days and Tab Tramadol 50 mg SOS for breakthrough pain. Patients are also administered broad spectrum antibiotics for three days and are usually discharged on the same day after recovery from anesthesia. The dressing on external opening is changed as required. Patients are followed up at 1 week, 1 month, 3 months, 6 months, 1 year and whenever recurrence of symptoms necessitates care.

Discussion

Traditional surgical procedures for anal fistulae include fistulotomy for superficial fistulae, fistulectomy for complex and deep fistulae and staged fistulotomy with seton placement for high fistulae. The aforementioned procedures inherently lead to perianal wounds that require regular change of dressings and long-term follow up. Pain, discomfort and prolonged time off work are natural sequelae of these surgical procedures. Fecal incontinence is a significant complication in these patients, especially in complex and recurrent fistulae.[6] This results from division and injury to the musculature that constitutes the sphincter mechanism of the anal canal.

The minimally invasive anal fistula treatment was initially described by *Meinero*.[6] He states that "*The rationale of the video-assisted anal fistula treatment technique is based on the same principles as other procedures for closing the internal opening and obliterating the tract, where the real innovation is constituted by a precise identification of the fistula anatomy and of the internal opening by fistuloscopy and fulguration of the tract walls under direct vision*".[6]

VAAFT qualifies as a true minimally invasive surgical procedure. There are no iatrogenic incisions incurred to gain access to the site of operative treatment. Surgical access is obtained via the pre-existing pathological opening of the fistula.

The essential features of the VAAFT technique include

- Fistuloscopic exploration of the fistula track.
- Identification of the internal fistula opening.
- Identification of secondary fistula tracks and abscess cavities.
- Fulguration and destruction of the fistula track under direct vision and
- securely stapled closure of the internal fistula opening.

Fistuloscopy with irrigation facilitates accurate identification and localization of the internal fistula opening in the anal canal. In difficult circumstances, digital probing of the anal canal to locate the tip of the fistuloscope is helpful. Also, the transillumination effect of the fistuloscopic light shining through the bowel wall may aid in localizing the internal fistula opening. Based on our experience, we could not identify the internal fistula opening in 24% of patients. This is assumed to arise from a spontaneous closure of the internal opening. In patients, where the light of the fistuloscope can be seen transilluminating through a very thin layer of mucosa, it may be advisable to secure the mucosal site by reinforcement with an endostapler. If there is no transillumination visible on the bowel wall from the light of the fistuloscope, one should refrain from creating an artificial internal opening of the fistula. In these patients, only fulguration and debridement of the fistula tract may be performed. Patients in whom the internal fistula opening is not identified, are found to have a higher risk of recurrence. The 8°-viewing angle of the fistuloscope is very useful in the detection of secondary tracks and abscess cavities, thereby reducing the risk of recurrence. The fistulous tract is distructed by fulguration under direct vision. Debridement of the fulgurated tract is performed using flexible fistula brush for a curved tract and Volkmann's spoon for a straight track. A securely stapled closure ensures hermetic occlusion of the internal fistula opening.

VAAFT in the management of anal fistulae is a new and evolving technique. As with many other new surgical techniques, users need to go through a learning curve. In our experience, which is based on a group of 416 patients, in 5 patients the internal opening of the anal fistula was very high (beyond the reach of anoscope). This condition precludes the option of a securely stapled closure of the internal opening. At present, the definitive endoscopic surgical management of such patients remains unresolved. Furthermore, in early stages of the surgeon's learning curve with VAAFT, there is an elevated risk that the internal fistula opening may not be identified. Also, secondary fistula tracks may be missed. These factors contribute to a higher recurrence rate in patients undergoing treatment during the initial learning phase of the surgeon. However, the resultant morbidity is limited as there are no perianal wounds and the musculature of the anal sphincter remains intact. This is of significance as the incidence of faecal incontinence is high with other surgical treatment options available.[11]

VAAFT involves an initial expenditure for purchasing the required equipment. However, the fistuloscope and ancillary equipment are reusable and the initial costs are likely to be recovered soon. The technique provides significant advantages to patients in terms of reduced pain, minimal morbidity and earlier resumption of normal activities. The global socioeconomic costs of this procedure are therefore likely to be low.

VAAFT is safe and feasible and can be mostly performed as a day care procedure. There are distinct advantages to patients in terms of reduced pain, absence of perianal wounds, faster recovery and earlier return to work. However, applicability of VAAFT in very high extrasphincteric fistulae remains unclear at present. Long-term results from more centers are awaited.

References

1. AGUILAR PS, PLASENCIA G, HARDY TG, JR., HARTMANN RF, STEWART WR. Mucosal advancement in the treatment of anal fistula. Dis Colon Rectum. 1985;28(7):496–8.
2. BLEIER JI, MOLOO H, GOLDBERG SM. Ligation of the intersphincteric fistula tract: an effective new technique for complex fistulas. Dis Colon Rectum. 2010;53(1):43–6.
3. GOLIGHER JC, DUTHIE HL, NIXON HH. Surgery of the anus, rectum, and colon. London: Baillière Tindall; 1975.
4. JOY HA, WILLIAMS JG. The outcome of surgery for complex anal fistula. Colorectal Dis. 2002;4(4):254–61.
5. LILIUS HG. Fistula-in-ano, an investigation of human foetal anal ducts and intramuscular glands and a clinical study of 150 patients. Acta Chir Scand Suppl. 1968;383:7–88.
6. MEINERO P, MORI L. Video-assisted anal fistula treatment (VAAFT): a novel sphincter-saving procedure for treating complex anal fistulas. Tech Coloproctol. 2011;15(4):417–22.
7. MILLIGAN II C, MORGAN CN. Surgical anatomy of the anal canal with special reference to anorectal fistulae. Lancet. 1934;2(1150 1156):1213–17.
8. MIZRAHI N, WEXNER SD, ZMORA O, DA SILVA G, EFRON J, WEISS EG, et al. Endorectal advancement flap: are there predictors of failure? Dis Colon Rectum. 2002;45(12):1616–21.
9. OZUNER G, HULL TL, CARTMILL J, FAZIO VW. Long-term analysis of the use of transanal rectal advancement flaps for complicated anorectal/vaginal fistulas. Dis Colon Rectum. 1996;39(1):10–4.
10. PARKS AG, GORDON PH, HARDCASTLE JD. A classification of fistula-in-ano. Br J Surg. 1976;63(1):1–12.
11. RITCHIE RD, SACKIER JM, HODDE JP. Incontinence rates after cutting seton treatment for anal fistula. Colorectal Dis. 2009;11(6):564–71.
12. ROJANASAKUL A. LIFT procedure: a simplified technique for fistula-in-ano. Tech Coloproctol. 2009;13(3):237–40.
13. ROJANASAKUL A, PATTANAARUN J, SAHAKITRUNGRUANG C, TANTIPHLACHIVA K. Total anal sphincter saving technique for fistula-in-ano; the ligation of intersphincteric fistula tract. J Med Assoc Thai. 2007;90(3):581–6.
14. SCHOUTEN WR, ZIMMERMAN DD, BRIEL JW. Transanal advancement flap repair of transsphincteric fistulas. Dis Colon Rectum. 1999;42(11):1419–22; discussion 22–3.
15. SHANWANI A, NOR AM, AMRI N. Ligation of the intersphincteric fistula tract (LIFT): a sphincter-saving technique for fistula-in-ano. Dis Colon Rectum. 2010;53(1):39–42.
16. SONODA T, HULL T, PIEDMONTE MR, FAZIO VW. Outcomes of primary repair of anorectal and rectovaginal fistulas using the endorectal advancement flap. Dis Colon Rectum. 2002;45(12):1622–8.
17. STELZNER F. Die anorektalen Fisteln. 1st ed. Berlin Heidelberg New York: Springer Verlag; 1959.
18. THOMPSON HR. The orthodox conception of fistula-in-ano and its treatment. Proc Roy Soc Med. 1962;55: 754–6.

VAAFT Instrument Set for Video-Assisted Anal Fistula Treatment

IMAGE1 S Camera System and Accessories

Instrument Set for Video-Assisted Anal Fistula Treatment (VAAFT)

24511 **Fistulectomy Set,**
including:
Fistuloscope 8°, angled eyepiece, outer diameter 3.3 × 4.7 mm, working length 18 cm, **autoclavable,** with straight instrument channel for instruments up to diameter 2.5 mm, fiber optic light transmission incorporated, color code: green,
Wire Tray for Cleaning, Sterilization and Storage
Obturator

24511AA **Fistuloscope** 8°, angled eyepiece, outer diameter 3.3 × 4.7 mm, working length 18 cm, **autoclavable,** with straight working channel channel for instruments up to diameter 2.5 mm, fiber optic light transmission incorporated, color code: green

100020-10 **Endoscopic Seal,** for single use, for working channels for 4 – 10 Fr. instruments, sterile, package of 10

24512 **Handle**

24513 **Obturator,** for endoscope

24515 **Coagulation Electrode,** 7 Fr., for fistulectomy

It is recommended to check the suitability of the product for the intended procedure prior to use.

Instrument Set for Video-Assisted Anal Fistula Treatment (VAAFT)

24514 **Fistula Brush,** with handle
including:
3-Ring Handle
Outer Sheath
3x **Fistula Brush Inserts,**
with 4 mm, 4.5 mm and 5 mm outer diameter

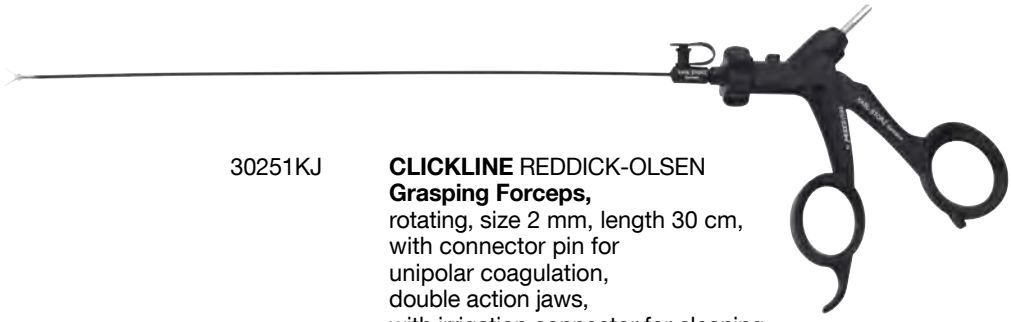

30251KJ **CLICKLINE** REDDICK-OLSEN
Grasping Forceps,
rotating, size 2 mm, length 30 cm,
with connector pin for
unipolar coagulation,
double action jaws,
with irrigation connector for cleaning
including:
Plastic Handle, without ratchet
Outer Sheath with Working Insert, insulated

24981 AUCKLAND EASI **Anal Distending Speculum,**
for anal examinations, with 3 blades, outer diameter 27 mm,
working length 6 cm, with Obturator 24981O, with ratchet



39501XP **Wire Tray for Cleaning, Sterilization and Storage,**
with integrated cleaning adaptor for washer-disinfector, with lid,
Spare Parts Basket 39501XS and silicone telescope holders,
external dimensions (w x d x h): 460 x 150 x 80 mm,
for instruments with up to 27 cm working length

IMAGE1 S Camera System

IMAGE1 S

Economical and future-proof

- Modular concept for flexible, rigid and 3D endoscopy as well as new technologies
- Forward and backward compatibility with video endoscopes and FULL HD camera heads
- Sustainable investment
- Compatible with all light sources

Innovative Design

- Dashboard: Complete overview with intuitive menu guidance
- Live menu: User-friendly and customizable
- Intelligent icons: Graphic representation changes when settings of connected devices or the entire system are adjusted
- Automatic light source control
- Side-by-side view: Parallel display of standard image and the Visualization mode
- Multiple source control: IMAGE1 S allows the simultaneous display, processing and documentation of image information from two connected image sources, e.g., for hybrid operations

Dashboard

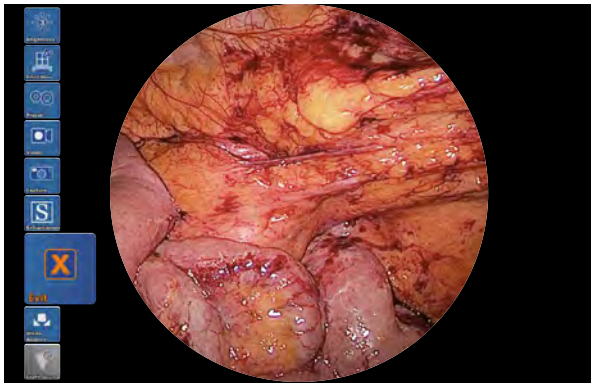

Live menu



Intelligent icons

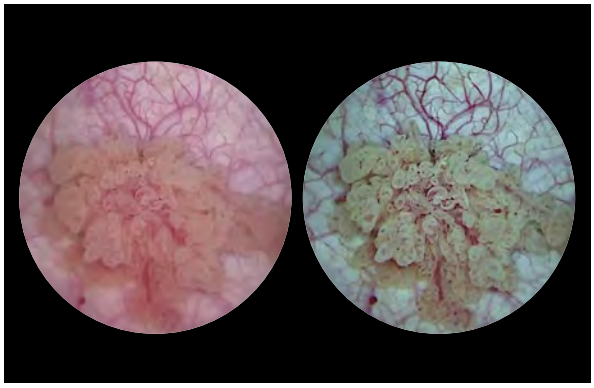

Side-by-side view: Parallel display of standard image and Visualization mode

IMAGE1 S Camera System

IMAGE1 S

FuLL HD Imaging

- **Very high quality of endoscopic images in FULL HD**
- **Natural color rendition**
- **Reflection is minimized**
- **Multiple IMAGE1 S technologies for homogeneous illumination, contrast enhancement and color shifting**

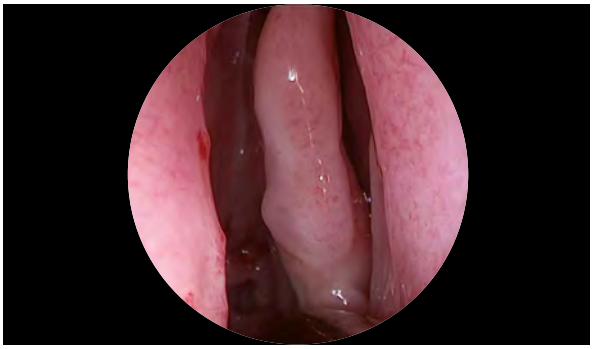

FULL HD image

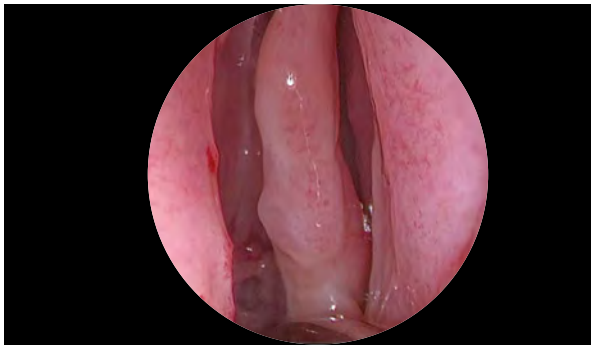

CLARA

FULL HD image

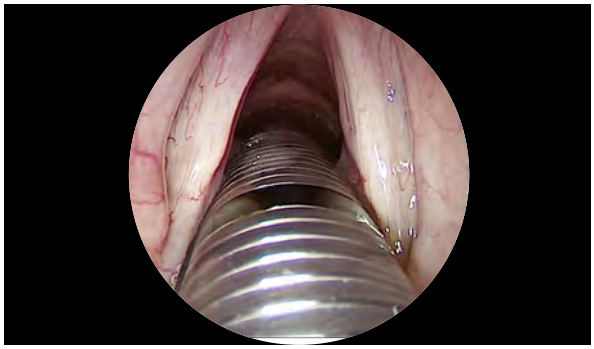

CHROMA

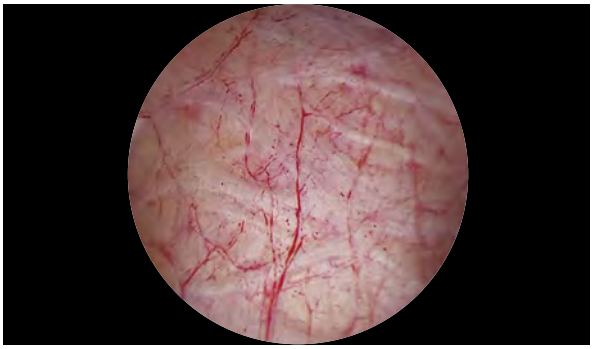

FULL HD image

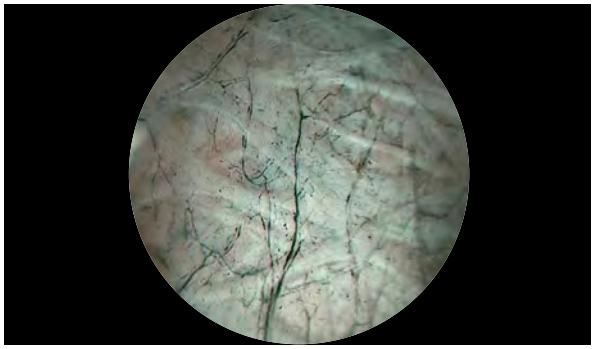

*SPECTRA A**

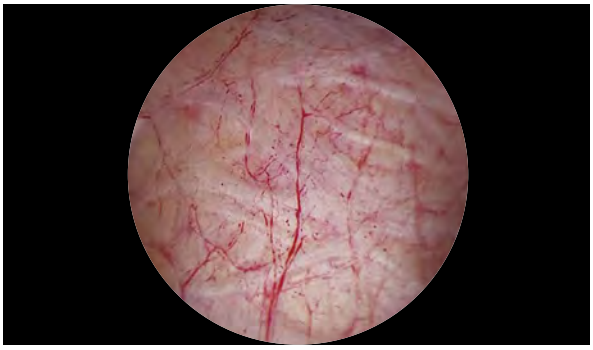

FULL HD image

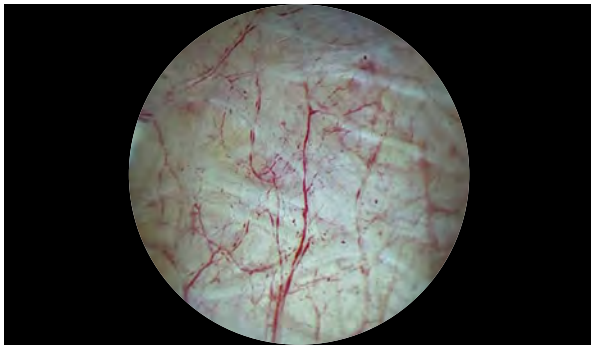

*SPECTRA B***

* *SPECTRA A:* **Not for sale in the U.S.**
** *SPECTRA B:* **Not for sale in the U.S.**

IMAGE1 S Camera System

TC 200EN

TC200EN* **IMAGE1 S CONNECT**, connect module, for use with up to 3 link modules, resolution 1920 x 1080 pixels, with integrated KARL STORZ-SCB and digital Image Processing Module, power supply 100–120 VAC/200–240 VAC, 50/60 Hz including:
Mains Cord, length 300 cm
DVI-D Connecting Cable, length 300 cm
SCB Connecting Cable, length 100 cm
USB Flash Drive, 32 GB, USB silicone keyboard, with touchpad, US

***Available in the following languages:** DE, ES, FR, IT, PT, RU

Specifications:

HD video outputs	- 2x DVI-D - 1x 3G-SDI
Format signal outputs	1920 x 1080p, 50/60 Hz
LINK video inputs	3x
USB interface SCB interface	4x USB, (2x front, 2x rear) 2x 6-pin mini-DIN

Power supply	100–120 VAC/200–240 VAC
Power frequency	50/60 Hz
Protection class	I, CF-Defib
Dimensions w x h x d	305 x 54 x 320 mm
Weight	2.1 kg

For use with IMAGE1 S
IMAGE1 S CONNECT Module TC200EN

TC 300

TC300 **IMAGE1 S H3-LINK,** link module, for use with IMAGE1 FULL HD three-chip camera heads, power supply 100–120 VAC/200–240 VAC, 50/60 Hz, **for use with IMAGE1 S CONNECT** TC200EN including:
Mains Cord, length 300 cm
Link Cable, length 20 cm

Specifications:

Camera System	**TC300 (H3-Link)**
Supported camera heads/video endoscopes	TH100, TH101, TH102, TH103, TH104, TH106 (fully compatible with IMAGE1 S) **22**2200 55-3, **22**2200 56-3, **22**2200 53-3, **22**2200 60-3, **22**2200 61-3, **22**2200 54-3, **22**2200 85-3 (compatible without IMAGE1 S technologies CLARA, CHROMA, SPECTRA*)
LINK video outputs	1x
Power supply	100–120 VAC/200–240 VAC
Power frequency	50/60 Hz
Protection class	I, CF-Defib
Dimensions (w x h x d)	305 x 54 x 320 mm
Weight	1.86 kg

* *SPECTRA A:* **Not for sale in the U.S.**
** *SPECTRA B:* **Not for sale in the U.S.**

IMAGE1 S Camera Heads

For use with IMAGE1 S Camera System
IMAGE1 S CONNECT Module TC200EN, **IMAGE1 S H3-LINK Module** TC300
and with all IMAGE1 HUB™ HD Camera Control Units

TH100

TH100 **IMAGE1 S H3-Z Three-Chip FULL HD Camera Head,** 50/60 Hz, IMAGE1 S compatible, progressive scan, soakable, gas- and plasma-sterilizable, with integrated Parfocal Zoom Lens, focal length f = 15–31 mm (2x), 2 freely programmable camera head buttons, for use with IMAGE1 S and IMAGE1 HUB™ HD/HD

Specifications:

IMAGE1 FULL HD Camera Heads	IMAGE1 S H3-Z
Product no.	TH100
Image sensor	3x ⅓" CCD chip
Dimensions w x h x d	39 x 49 x 114 mm
Weight	270 g
Optical interface	integrated Parfocal Zoom Lens, f = 15–31 mm (2x)
Min. sensitivity	F 1.4/1.17 Lux
Grip mechanism	standard eyepiece adaptor
Cable	non-detachable
Cable length	300 cm

TH104

TH104 **IMAGE1 S H3-ZA Three-Chip FULL HD Camera Head,** 50/60 Hz, IMAGE1 S compatible, **autoclavable,** progressive scan, soakable, gas- and plasma-sterilizable, with integrated Parfocal Zoom Lens, focal length f = 15–31 mm (2x), 2 freely programmable camera head buttons, for use with IMAGE1 S and IMAGE1 HUB™ HD/HD

Specifications:

IMAGE1 FULL HD Camera Heads	IMAGE1 S H3-ZA
Product no.	TH104
Image sensor	3x ⅓" CCD chip
Dimensions w x h x d	39 x 49 x 100 mm
Weight	299 g
Optical interface	integrated Parfocal Zoom Lens, f = 15–31 mm (2x)
Min. sensitivity	F 1.4/1.17 Lux
Grip mechanism	standard eyepiece adaptor
Cable	non-detachable
Cable length	300 cm

Monitors

9619NB **19" HD Monitor,**
color systems **PAL/NTSC,** max. screen resolution 1280 x 1024, image format 4:3, power supply 100–240 VAC, 50/60 Hz, wall-mounted with VESA 100 adaption, including:
External 24 VDC Power Supply
Mains Cord

9826NB **26" FULL HD Monitor,**
wall-mounted with VESA 100 adaption, color systems **PAL/NTSC,**
max. screen resolution 1920 x 1080, image fomat 16:9,
power supply 100–240 VAC, 50/60 Hz including:
External 24 VDC Power Supply
Mains Cord

Monitors

KARL STORZ HD and FULL HD Monitors	19"	26"
Wall-mounted with VESA 100 adaption	9619NB	9826NB
Inputs:		
DVI-D	●	●
Fibre Optic	–	–
3G-SDI	–	●
RGBS (VGA)	●	●
S-Video	●	●
Composite/FBAS	●	●
Outputs:		
DVI-D	●	●
S-Video	●	–
Composite/FBAS	●	●
RGBS (VGA)	●	–
3G-SDI	–	●
Signal Format Display:		
4:3	●	●
5:4	●	●
16:9	●	●
Picture-in-Picture	●	●
PAL/NTSC compatible	●	●

Optional accessories:

9826SF **Pedestal,** for monitor 9826NB
9626SF **Pedestal,** for monitor 9619NB

Specifications:

KARL STORZ HD and FULL HD Monitors	19"	26"
Desktop with pedestal	optional	optional
Product no.	9619NB	9826NB
Brightness	200 cd/m² (typ)	500 cd/m² (typ)
Max. viewing angle	178° vertical	178° vertical
Pixel distance	0.29 mm	0.3 mm
Reaction time	5 ms	8 ms
Contrast ratio	700:1	1400:1
Mount	100 mm VESA	100 mm VESA
Weight	7.6 kg	7.7 kg
Rated power	28 W	72 W
Operating conditions	0–40°C	5–35°C
Storage	-20–60°C	-20–60°C
Rel. humidity	max. 85%	max. 85%
Dimensions w x h x d	469.5 x 416 x 75.5 mm	643 x 396 x 87 mm
Power supply	100–240 VAC	100–240 VAC
Certified to	EN 60601-1, protection class IPX0	EN 60601-1, UL 60601-1, MDD93/42/EEC, protection class IPX2

Cold Light Fountain Power LED 175 SCB

201614 01-1	**Cold Light Fountain Power LED 175 SCB,** with integrated SCB, high-performance LED and one KARL STORZ light outlet, power supply 110–240 VAC, 50/60 Hz including: **Cold Light Fountain Power LED** **Mains Cord** **SCB Connecting Cable,** length 100 cm
201320 26	**Xenon-Spare-Lamp,** 175 Watt, 15 Volt
495NL	**Fiber Optic Light Cable,** diameter 3.5 mm, length 180 cm
495NA	**Fiber Optic Light Cable,** diameter 3.5 mm, length 230 cm

AUTOCON® II 400 SCB

205352 01-125	**AUTOCON® II 400 High End, Set SCB** power supply 220 - 240 VAC, 50/60 Hz, HF connecting sockets: Bipolar combination, Multifunction, Unipolar 3-pin + Erbe Neutral electrode combination 6.3 mm, jack and 2-pin, System requirements: SCB R-UI Software Release 20090001-43 or higher including: **AUTOCON® II 400,** with KARL STORZ SCB **Mains Cord** **SCB Connecting Cable, length 100 cm**

Necessary Accessories:

200178 31	**Three-Pedal Footswitch,** for use with HF generators AUTOCON® II 400 and AUTOCON® II 200

Equipment Cart

UG220

UG220

Equipment Cart
wide, high, rides on 4 antistatic dual wheels
equipped with locking brakes 3 shelves,
mains switch on top cover,
central beam with integrated electrical subdistributors
with 12 sockets, holder for power supplies,
potential earth connectors and cable winding
on the outside,

Dimensions:
Equipment cart: 830 x 1474 x 730 mm (w x h x d),
shelf: 630 x 510 mm (w x d),
caster diameter: 150 mm

inluding:

Base module equipment cart, wide
Cover equipment, equipment cart wide
Beam package equipment, equipment cart high
3x **Shelf,** wide
Drawer unit with lock, wide
2x **Equipment rail,** long
Camera holder

UG540

UG540

Monitor Swifel Arm,
height and side adjustable,
can be turned to the left or the right side,
swivel range 180°, overhang 780 mm,
overhang from centre 1170 mm,
load capacity max. 15 kg,
with monitor fixation VESA 5/100,
for usage with equipment carts UG xxx

Recommended Accessories for Equipment Cart

UG310

UG310 **Isolation Transformer,**
200 V–240 V; 2000 VA with 3 special mains socket,
expulsion fuses, 3 grounding plugs,
dimensions: 330 x 90 x 495 mm (w x h x d),
for usage with equipment carts UGxxx

UG410

UG410 **Earth Leakage Monitor,**
200 V–240 V, for mounting at equipment cart,
control panel dimensions: 44 x 80 x 29 mm (w x h x d),
for usage with isolation transformer UG310

UG510

UG510 **Monitor Holding Arm,**
height adjustable, inclinable,
mountable on left or right,
turning radius approx. 320°, overhang 530 mm,
load capacity max. 15 kg,
monitor fixation VESA 75/100,
for usage with equipment carts UGxxx

Notes:

Notes:

Notes:

Notes:

with the compliments of

KARL STORZ — ENDOSKOPE