Endo Press®

OPEN RHINOPLASTY AND CARTILAGE GRAFTING



Gilbert AIACH

Some of the drawings and photographs used in this brochure were taken from the following books with the kind permission of my editor, Masson, Paris.

G. AIACH: Atlas de Rhinoplastie et de la voie d'abord externe 2ème éd., Masson. Paris,1996.

G. AIACH: Atlas of Rhinoplasty. Open and endonasal approaches. Quality Medical Publishing, Inc., St. Louis, Missouri, 1996, revised edition 2000

G. AIACH: Atlante di Rhinoplastica e della via d'accesso esterna. Masson (Ed.), Milano, 1994

G. AIACH: Atlas de Rhinoplastia y de la via abordaje externo. Masson (Ed.), Madrid, 1994.

Important notes:

Medical knowledge is ever changing. As new research and clinical experience broaden our knowledge, changes in treatment and therapy may be required. The authors and editors of the material herein have consulted sources believed to be reliable in their efforts to provide information that is complete and in accord with the standards accepted at the time of publication. However, in view of the possibility of human error by the authors, editors, or publisher, or changes in medical knowledge, neither the authors, editors, publisher, nor any other party who has been involved in the preparation of this booklet, warrants that the information contained herein is in every respect accurate or complete, and they are not responsible for any errors or omissions or for the results obtained from use of such information. The information contained within this booklet is intended for use by doctors and other health care professionals. This material is not intended for use as a basis for treatment decisions, and is not a substitute for professional consultation and/or use of peer-reviewed medical literature.

Some of the product names, patents, and registered designs referred to in this booklet are in fact registered trademarks or proprietary names even though specific reference to this fact is not always made in the text. Therefore, the appearance of a name without designation as proprietary is not to be construed as a representation by the publisher that it is in the public domain.

The use of this booklet as well as any implementation of the information contained within explicitly takes place at the reader's own risk. No liability shall be accepted and no guarantee is given for the work neither from the publisher or the editor nor from the author or any other party who has been involved in the preparation of this work. This particularly applies to the content, the timeliness, the correctness, the completeness as well as to the quality. Printing errors and omissions cannot be completely excluded. The publisher as well as the author or other copyright holders of this work disclaim any liability, particularly for any damages arising out of or associated with the use of the medical procedures mentioned within this booklet.

Any legal claims or claims for damages are excluded.

In case any references are made in this booklet to any 3rd party publication(s) or links to any 3rd party websites are mentioned, it is made clear that neither the publisher nor the author or other copyright holders of this booklet/book endorse in any way the content of said publication(s) and/or web sites referred to or linked from this booklet and do not assume any form of liability for any factual inaccuracies or breaches of law which may occur therein. Thus, no liability shall be accepted for content within the 3rd party publication(s) or 3rd party websites and no guarantee is given for any other work or any other websites at all.

Open Rhinoplasty and Cartilage Grafting

Gilbert AIACH, M.D.,
Chirurgie esthétique et plastique
76, Avenue Raymond Poincaré
F-75116 Paris, France
Phone: +33 (1) 45 53 57 57
Fax: +33 (1) 47 55 18 60
E-mail: gaiach@club-internet.fr

© 2010 Endo:Press® Tuttlingen
ISBN 978-3-89756-050-5, Printed in Germany
P.O. Box D-78503 Tuttlingen
Phone: +49 (0) 7461/14590
Fax: +49 (0) 7461/708-529
E-Mail: Endopress@t-online.de

Editions in languages other than English and German are in preparation. For up-to-date information, please contact Endo:Press® Tuttlingen, Germany, at the address indicated above.

Typesetting and Lithography:
Endo:Press®, D-78532 Tuttlingen, Germany
Eller repro+druck
D-78056 VS-Schwenningen, Germany

Printed by:
Straub Druck+Medien AG
D-78713 Schramberg, Germany

1.0 11.10-1

Content

Fig. 1

Introduction

The aim of rhinoplasty is to establish certain aesthetic results while preserving satisfactory nasal function. Just as in all other procedures of aesthetic surgery, there is no magic formula in rhinoplasty, and it is important that the surgeon has detailed knowledge of the techniques and thinks in terms of balance: not so much the volume is important as the harmony of volumes.

Aesthetic sense varies across civilizations and cultures; but there are certain criteria and rules of proportion that have remained unchanged since the Egyptians first applied mathematical principles in art and established the golden numbers, and since Leonardo da Vinci established proportions in the 16th century, which are still in use today. The artistic sense, even if innate, may be enhanced by the study of the dimensions and proportions of the face, and making models and sculptures may considerably further one‘s appreciation of proper and harmonious proportions.

The nasal pyramid may be seen as an assembly of different juxtaposed “subunits” including radix, dorsum, supra-tip area, tip lobule, columella, alar lobules, and lateral walls of the nose (**Fig. 1**).

These subunits or “volumes” should be maintained in a harmonious spatial balance not only relative to each other but also to the other volumes of the face which include the forehead, cheekbones, lips, and chin.

In order to obtain the proper balance, one may need to appropriately modify some or all of these volumes. Frequently, this requires a combination of reduction and augmentation of the subunits.

In 1934, *Emile Rethi* described a high transverse columellar incision in rhinoplasty, and the external approach has since been in common use in the surgical correction of sequellae of naso-labial clefts with asymmetric structures, where an endonasal approach is difficult. But the external incision was not readily accepted in aesthetic rhinoplasty, perhaps because the advantages of this trans-columellar incision in facilitating dissection and exposure of the osteo-cartilaginous structures had not been well exploited.

Nowadays, the external approach is used frequently and even routinely by many rhinoplastic surgeons.

The external approach provides excellent exposure with direct view of the lower lateral cartilages and middle vault as well as several technical advantages: the normal anatomy can be restored and this is achieved most often by repositioning the alar cartilages and precise placement and fixation of cartilage grafts (spreader graft and tip graft).

Besides sequellae of naso-labial clefts which have long been considered the major indication for the external incision, the best indications are small nostrils, nasal tip asymmetries, major septal deviations (in particular those of the anterior septal border), and difficult secondary rhinoplasties; however, the external approach can also be used in selected primary rhinoplasty procedures, especially where better exposure is needed.

Technical Issues

After marking the limits of the cartilages and the caudal border of the nasal bones, a stair-step columellar incision is placed in the middle of the columella or, alternatively, at its narrowest point, but always behind the apex of the nostrils.

Two landmarks are tattooed on either side of the incision close to the nostril using a needle tip impregnated with ink to preserve the continuity of the rim of the nostril during suturing (**Fig. 2**).

The endonasal injection is performed with a short speculum, initially proceeding along the outer surface of the alar cartilages after identification of the caudal border of the lateral crura, and continuing at the level of the membranous septum of the plica nasi and in the subperichondrial plane.

Injection and undermining should be performed in the anatomic planes, flush with cartilage and bone. These planes are: the extra-periosteal plane at the level of the proposed lateral osteotomy, the supra-perichondrial and periosteal planes, on the deep surface of the SMAS, and the sub-perichondrial and sub-periosteal planes at the level of the nasal mucosa (**Fig. 3**).

The caudal border of the lateral crus needs to be precisely localized by everting the nostril with a *double hook* while applying pressure in the opposite direction by placing a finger on the surface (**Figs. 4+6c**).

The infra-cartilaginous incisions and soft tissue dissections are performed as in a delivery technique. At the level of the columella, however, the incision made in the vestibular skin is placed 1–1.5 mm from the roll of the nostril in order to preserve a small segment of vestibular skin which is useful for final suturing after tip grafting (**Fig. 5**).


Fig. 2

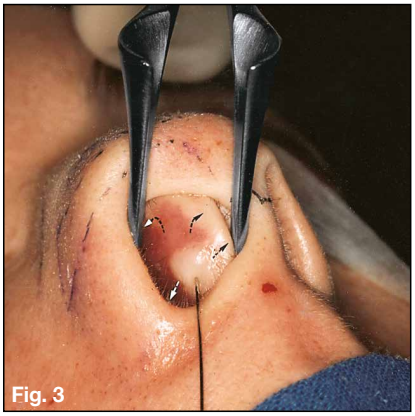
Fig. 3

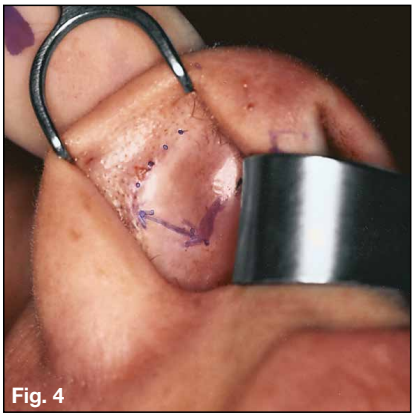
Fig. 4

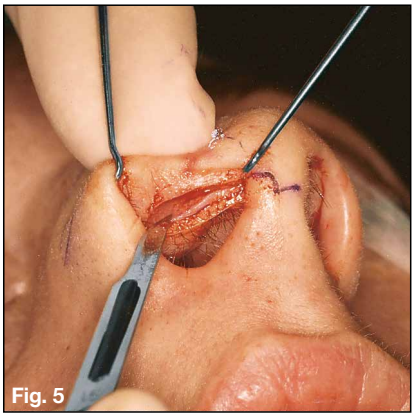
Fig. 5

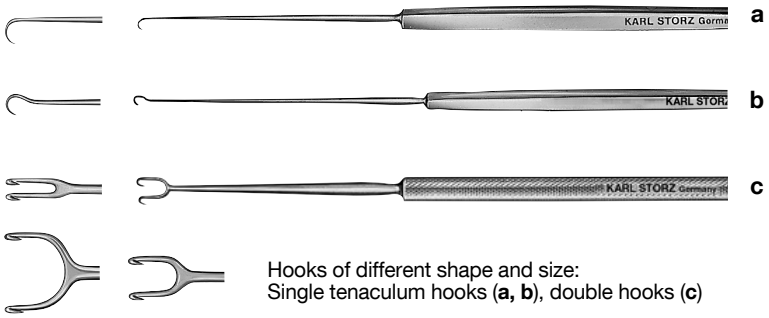

Hooks of different shape and size:
Single tenaculum hooks (**a, b**), double hooks (**c**)

Fig. 6

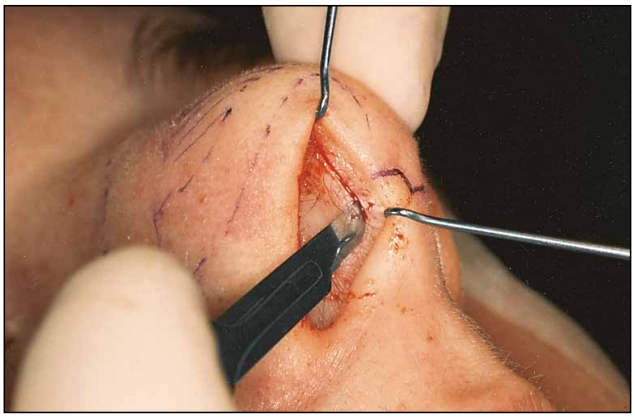

Fig. 7a

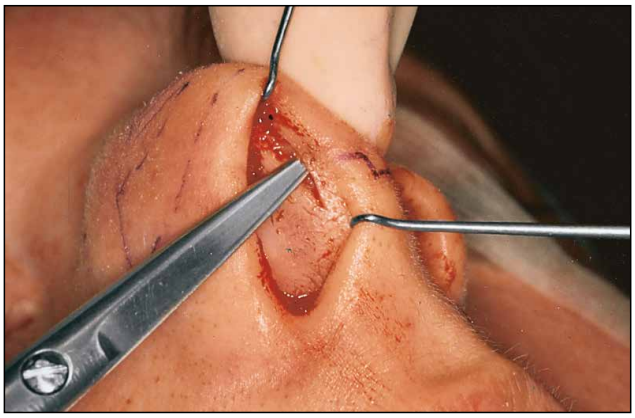

Fig. 7b

The vestibular skin of the medial crura is then separated from the cartilage with *sharp-pointed scissors* to facilitate final suture of the skin.

The trans-columellar incision is made to join the medial ends of the two marginal incisions; the dissection is performed in the plane directly above the perichondrium covering the medial crura (**Figs. 7a+b**).

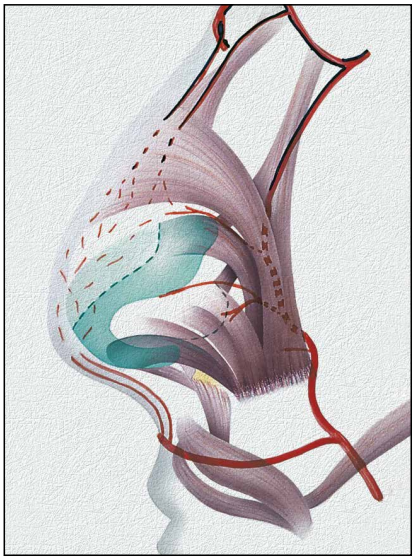

Fig. 8

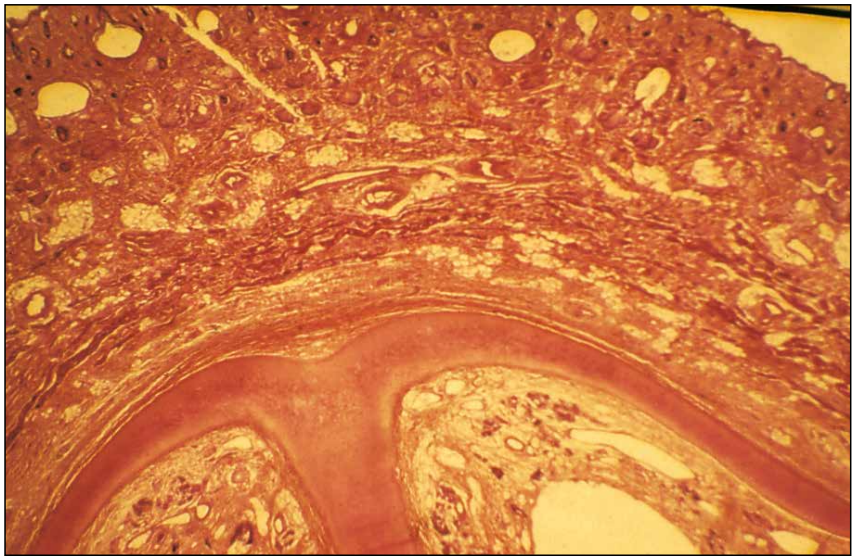

Fig. 9

The dissection should not extend laterally beyond the tail of the lateral crura in the interest of preserving the cutaneous and muscular attachments of the cartilage.

The dissection is then extended upwards in the plane located below the SMAS; the extent of the dissection narrows when approaching the root. The dissection should permit resection of the hump or placement of a graft (**Figs. 8+9**).

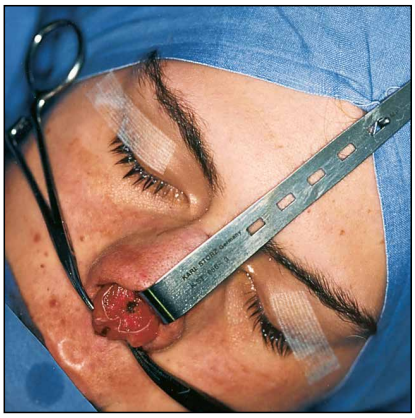

Fig. 10a

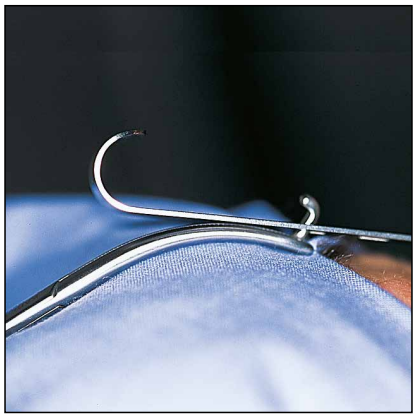

Fig. 10b

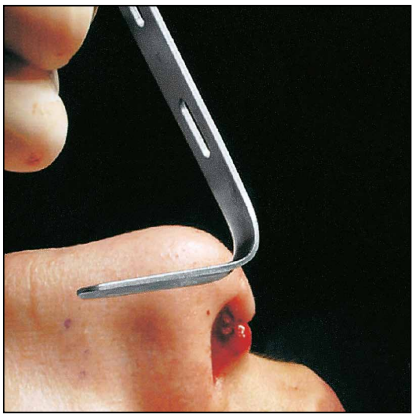

Fig. 10c

Exposure is obtained by using the *"S"-shaped nasal retractor* attached to self-retaining forceps, and two hemostats attached to the soft tissue to pull the domes in a lateral direction (**Figs. 10a–c**).

The anatomy of the lateral crura and the medial crura is well visualized. Deformities and asymmetries that were not detected or were minimal on external examination are often encountered: the medial crura can be irregular and twisted, mostly when tip projection is high. These deformities are freed up by dissection and become more pronounced. This explains certain secondary defects observed afterexteriorization with the delivery technique (**Fig 10e**).

AIACH **Nasal Retractor,** double-ended,
S-shaped, with perforations

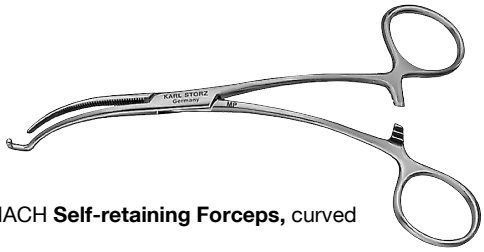

AIACH **Self-retaining Forceps,** curved

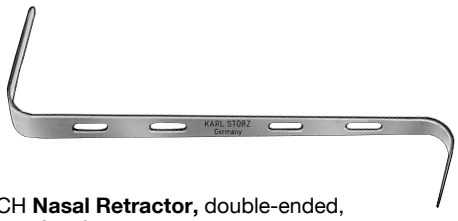

AIACH **Nasal Retractor,** double-ended,
with perforations

Fig. 10e

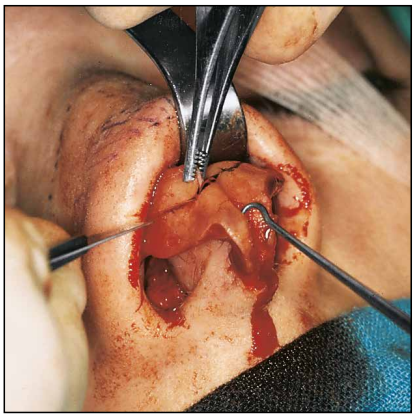

Fig. 11

Corrections of Alar Cartilage Deformities

By exposing the alar cartilages the surgeon can determine the appropriate type of correction to be performed and subsequently restore the anatomy by resecting the cephalic portion of the lateral crura with a cartilaginous incision, suture or graft.

The resection of cephalic excess tissue of the lateral crura can be performed symmetrically and should be governed by the configuration and condition of the cartilages (**Fig. 11**).

The most prominent point of the domes must be identified and the distance between the domes measured. This distance, if too large, can be further reduced by interdomal sutures. When the middle crura are long and divergent, the projection of the nasal tip can be increased by approximating and then suturing the domes in the desired position (**Fig. 12**).

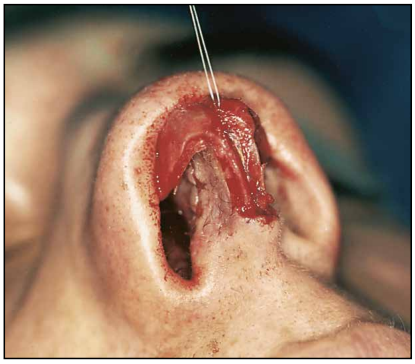

Fig. 12

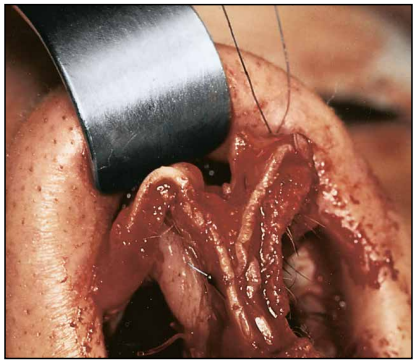

Fig. 13a

Fig. 13b

Narrowing sutures can be performed to correct wide domes or marked convexity of the lateral crura (**Figs. 13a+b**).

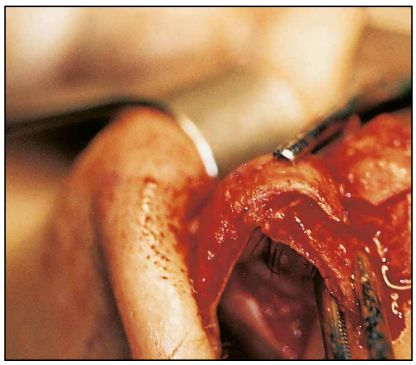

Fig. 14a

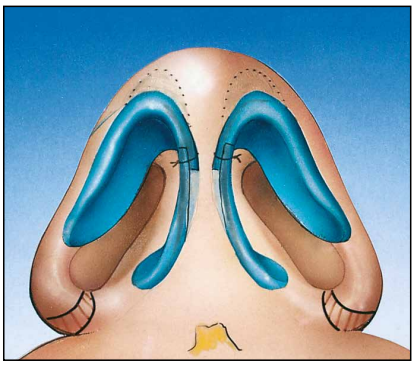

Fig. 14b

In high tip projection, the domes can be resected with much precision and the alar arch reestablished subsequently by placing a suture or overlapping the cut ends of the cartilages (**Figs. 14a+b**).

Nasal Hump Resection

There are various ways to resect a nasal hump. Use of the *nasal rasp* is preferred to reduce a small hump and if radix depression is normal. This instrument allows to complete resections which were started with the osteotome.

There are various types of rasps; the use of certain rasps bears the risk of avulsion and thus the procedure should be performed with adequate care. It is recommended to rasp in an oblique direction with respect to the axis of the nose. The diamond rasp allows to soften sharp bony edges (**Fig. 15**).

The osteotome (**Fig. 21,** p.10) allows 'en bloc' resection of a medium-sized or large bony hump, especially when the patient presents with a high radix. Using the osteotome in this way offers the advantage of clean cuts and no debris.

Problems encountered in the use of the osteotome are usually related to difficulties in the orientation of the instrument towards the nasion. Actually, the examination of the lateral cephalometric image (**Fig. 16**) shows the soft tissues to be thickest at the level of the root of the nose, which makes it difficult to determine the precise location of the bony nasion from outside. Soft tissue thickness of the radix varies between 3 and 9.5 mm with a mean of 7 mm in females and 7.5 mm in males.

Radiography of the nose with a straight dorsum shows that the osteo-cartilaginous profile is not straight, but slightly convex. This implies that when the surgeon follows the section lines at the level of the cartilaginous hump, the orientation of the osteotome at the inferior aspect of the nasal bones should be adjusted accordingly, i.e. the osteotome must be lifted slightly upwards.

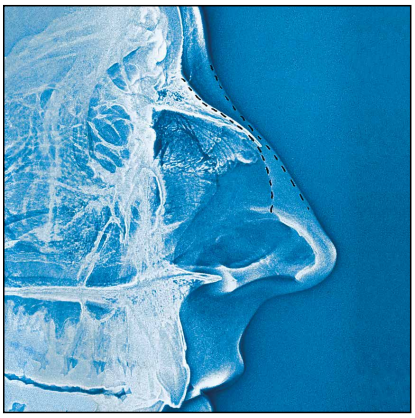

Fig. 16

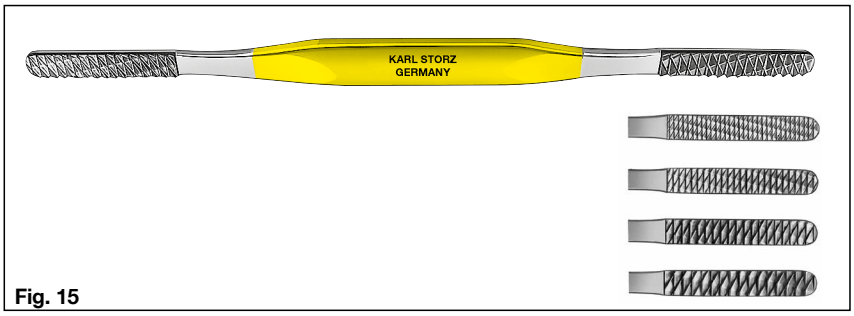

Fig. 15

Fig. 15
Nasal Rasp, tungsten carbide inserts, double-ended. Blades of different sizes and finish, (coarse, medium and fine) are available.

Fig. 17

Precise localization of the bony nasion from the outside is easily achieved with a *straight needle* passed horizontally through the soft tissues, flush with the bony radix (**Fig 17**). The external end of the needle precisely indicates the level of the nasion and, therefore, the point towards which the osteotome should be guided.

A nasal hump can be reduced using a specifically designed *osteotome* with an external guiding rod (**Fig. 21**). This T-shaped instrument is wider in its mid-portion to permit the passage of a semi-rigid guiding rod, which is restricted to the plane of the osteotome in its sliding motion. Consequently, this guiding rod determines in which direction to advance the osteotome towards the straight needle indicating the level of the nasion.

The blunt end of the guiding rod is located 7–8 mm from the blunted and smoothed corners of the cutting edge of the osteotome.

Since the guiding rod is semi-rigid, it is necessary to check its alignment with the blade of the osteotome before using the instrument. If unaligned, a small adjustment should be made by slightly bending the steel guiding rod.

The guiding rod is pulled back several centimeters and the osteotome is firmly inserted at the caudal border of the nasal bone.

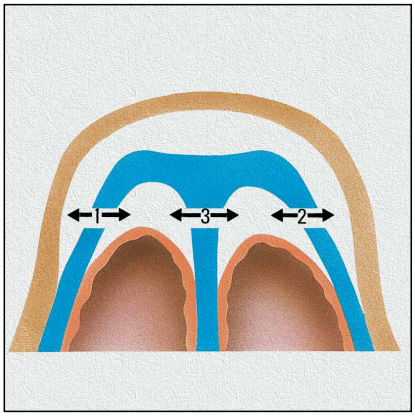

Fig. 18

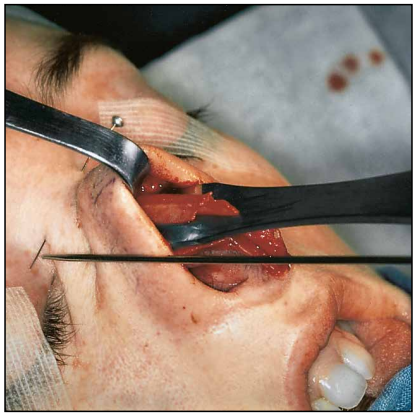

Fig. 19

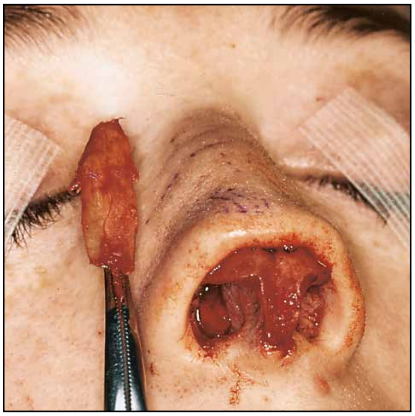

Fig. 20

The cartilaginous incisions are made with serrated scissors at the level of the upper lateral cartilages and at the anterior border of the septum. This procedure involves three steps; small or moderate humps can be reduced with a scalpel in a one-piece section that is both symmetric and precise.

The guiding rod of the osteotome is slid forward toward the nasion until it comes into contact with the straight needle.

The transverse portion of the osteotome facilitates precise horizontal positioning, and the resection can be carried out with a mallet (**Fig 19**).

After resection, the hump is removed with a hemostat by grasping the bony part so as to harvest the hump in one piece without damaging the specimen (**Fig 20**).

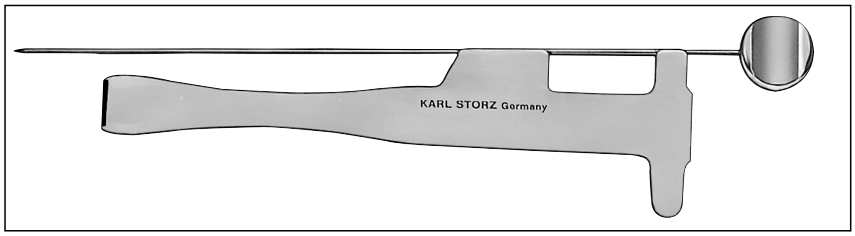

Fig. 21
AIACH **Osteotome for Hump Removal** with lateral guiding rod.

Septal Approach

Scrupulous attention to technique as well as adequate instrumentation and illumination are necessary at this important stage of the procedure.

The septum can be approached through its anterior border – this is easier to do once the hump has been resected – or after dissection of the anterior borders of the upper lateral cartilages. Dorsal access to the septum using an external approach affords remarkable exposure and is most suitable for certain deviations of the anterior septal border, in which the nostrils are small, and in secondary septoplasties. This approach also permits the harvest of graft material.

The domes and medial crura can be separated down to the nasal spine. Two hemostats attached to the soft tissues are used to retract the domes laterally, and the septal angle is located by making it project like a sawhorse under the taut soft tissues (**Fig. 22b**).

A short speculum is used in the vestibule and anterior part of the septum. A medium-sized speculum is used for observation and correction of the posterior part of the septum.

With the suction elevator. no. 498832 the dissection can be performed rapidly once the proper subperichondrial plane is identified (**Fig. 22a**).

In anterior septal border deviations and secondary septoplasties, the dorsal approach to the septum is very useful, since the upper lateral cartilages can be separated from the anterior septal border, allowing a direct approach to the anterior border of the septum. Correction of any septal deformities can be achieved with great precision by scoring to release the cartilage, or by resections, sutures or battens. Moreover, this procedure provides for good evaluation of the septal support and reconstruction of a rigid and straight septum (**Fig. 23**).

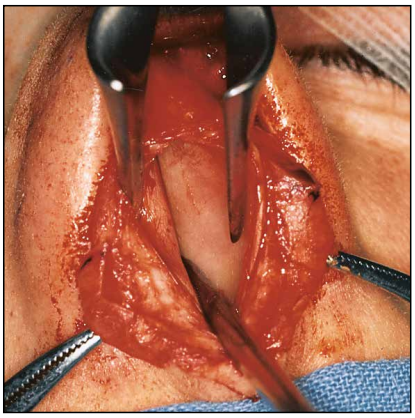

Fig. 22b

Fig. 23
An excellent exposure of the dorsal and caudal borders of the septum is obtained.

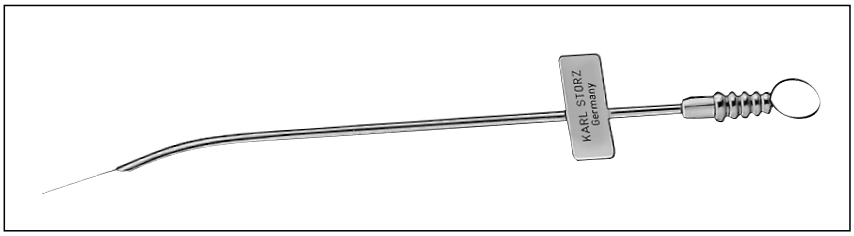

Fig. 22a
AIACH **Suction Elevator,** distal and slightly curved, with stylet.

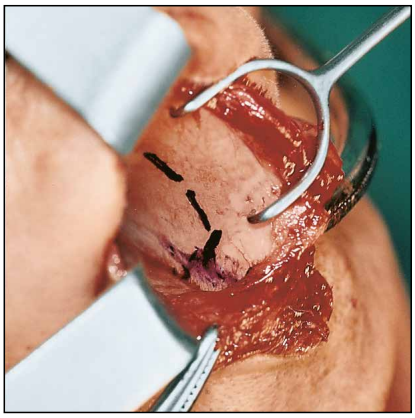

Fig. 24a

Septal Harvesting

- A cartilaginous incision is made 1 cm above and behind the caudal and dorsal border of the septum in order to preserve a sufficient septal buttress after resection (**Fig. 24a**),
- proceeding from this cartilaginous incision, the subperichondrium is undermined on the contralateral side and the incision is extended over the entire zone to be harvested, which can extend to the nasal floor (**Fig. 24b**).
- Once the mucosa has been undermined, two blades of a medium-sized nasal speculum are placed on either side of the septum. The septum is then sectioned with serrated scissors directed at an angle of 45°. Depending on the amount of graft material to be harvested, either a second section parallel and 1 to 1.5 cm behind the first section line can be performed or the cartilage separated at its junction with the vomer. The posterior section is done last, either at the junction of the perpendicular plate of the ethmoid and the vomer, or further posterior, where the bone is often thin and can be easily sectioned with the end of a sharp periosteal elevator (**Figs. 24b, 25a**).
- The fragment to be harvested is grasped with strong flat-jaw forceps (**Fig. 25b**). Gentle twisting motions of the instrument allow a fairly good-sized fragment to be extracted in one piece. The septal cartilage is often thicker posteriorly and inferiorly at the junction with the vomer at which it often is deflected to the left. The perpendicular plate of the ethmoid bone can provide a very thin bony fragment that is sometimes translucent and can be used over the lateral walls and also in the nasal ala.

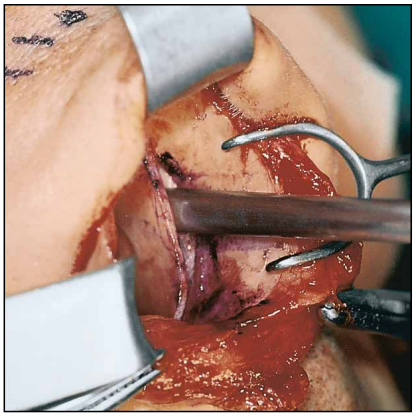

Fig. 24b



Fig. 25a
FREER **Elevator,** double-ended.

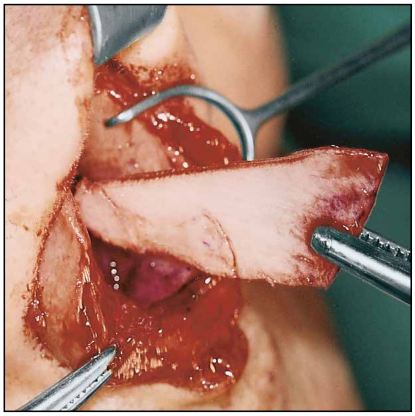

Fig. 24c

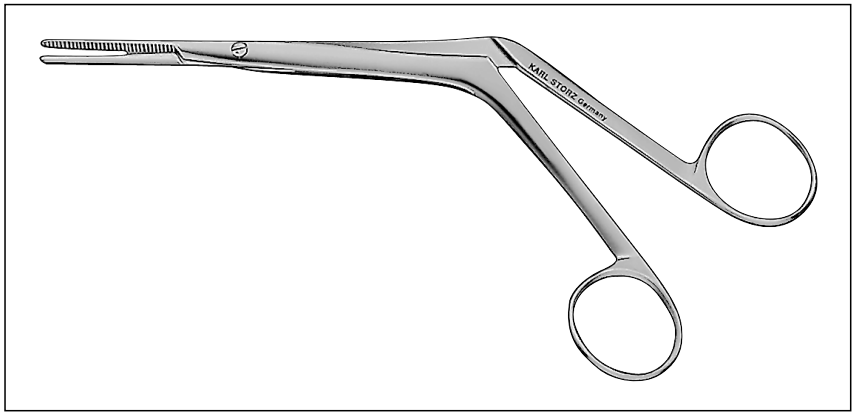

Fig. 25b
AIACH **Septal Material Harvesting Forceps,** angular, strong.

The vomer can be harvested separately with the KILLIAN-CLAUS bayonet septum chisel which allows section at the nasal floor (**Fig. 26a**).

After a posterior septal resection, a disinsertion or resection of the caudal border or mobilizing cartilaginous incisions, there is a risk of secondary deformity, weakening or recurrence of a deviation which can be prevented by various means:

- Cartilaginous sutures.
- An external suspension using two sutures passing through the septum and then over a support placed on the nasal bridge.
- Reinforcement with cartilaginous battens placed on either side of the septum.
- Dorsal and columellar cartilage grafts also allow the septal support to be reinforced.

Techniques of Cartilage Grafting

Autogenous grafts are frequently used to preserve and reconstruct the support structures of the nose as well as to contour, augment, and balance the different areas of the nose.

Cartilage grafting consists of several important steps:

Selection of autogenous material: because of its flat contour, septal cartilage is the material of choice for spreader grafts, columellar struts and dorsal grafts in which it can be used to produce multilayered grafts. Septal cartilage can be crushed and easily modeled without secondary distortion.

The septal cartilage can afford a large amount of flat, rigid grafting material, 1–3 mm thick and stiff enough to be a solid support; it also provides thin and flat bony fragments which are very convenient for reconstruction of lateral bony walls and provide support to the cartilaginous wall without bulging. These fragments are easily perforated on the working grid with a strong needle.

It is important to prepare a flat bony recipient site by rasping the dorsum and deepening the radix with a beveled osteotome (**Fig. 26d**). Any part of the septum projecting over the midline can be easily eliminated with the tenon-shaped end of the tenon mortise rasp (**Fig. 26c**). Dorsal prominences can also be eliminated with a narrow rasp (**Fig. 26b**).

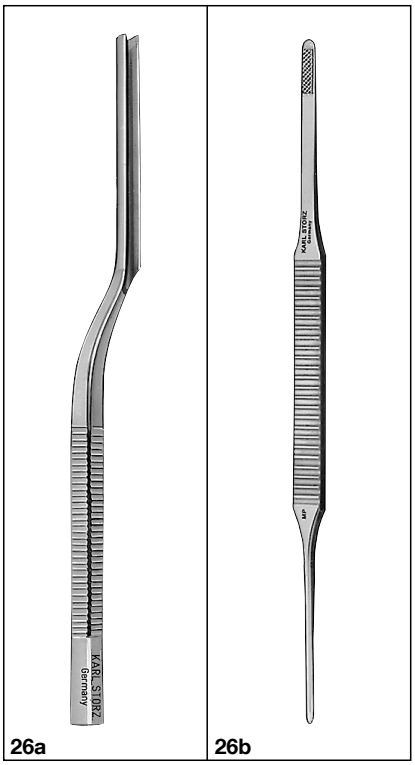

Fig. 26a
KILLIAN-CLAUS **Septum Chisel** with V-shaped cutting edge.

Fig. 26b
AIACH **Narrow Rasp,** double-ended, medium.

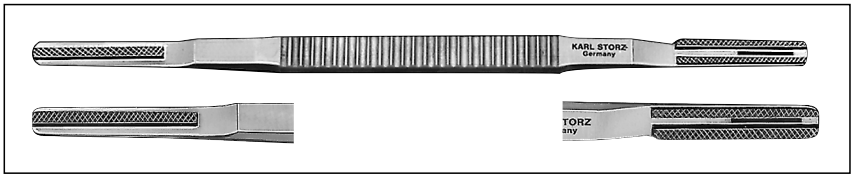

Fig. 26c
AIACH **Tenon Mortise Rasp,** double-ended, medium, one side with augmented teeth, other side slotted, without teeth.

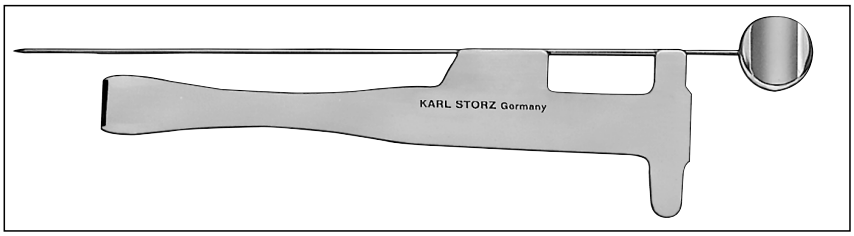

Fig. 26d
AIACH **Osteotome** for Hump Removal with lateral guiding rod.


Fig. 27a


Fig. 27b

The graft must then be carefully prepared with adequate instruments:

- *Atraumatic cartilage suture forceps*, for cartilage suture, with teeth and guiding ducts (**Fig. 28a**).
- *Working grid* (**Fig. 29**) for preparation of cartilage and bone grafts, graduated. *Cartilage graft forceps* with flat, slotted jaws (**Fig. 28b**).
- The graft can be anchored on the step of the grid and its edges beveled with a blade. A thick graft can be sliced off in the working grid‘s narrow area (depth 0.5 mm).

Dorsum and Radix

On the radix area: the graft is indicated to fill-in a low radix and sometimes to balance a large nasal hump or nasal base. The material of choice for grafting the radix should be a thin, flexible piece of cartilage. Crushed septal cartilage from the resected portions of the lateral crura can be used for this purpose (**Fig. 27a–c**).

Multilayered grafts can be placed in a criss-cross fashion after slight rasping of the soft tissues of the radix.

On the dorsum: the goal of a dorsal graft is to provide normal height and harmonious continuity with the radix by two curved and slightly divergent lines extending from the supraciliar ridges to the tip-defining points. The width of the graft is determined by the width of the radix and interdomal distance; the graft should not only cover an “open roof” but also blend with the adjacent areas.

The length, width, and thickness of the graft must be carefully designed to prevent over- or undercorrection. Suitable preoperative planning include profile cephalography, X-rays and modeling paste. Templates and sizers can be used in the operation.

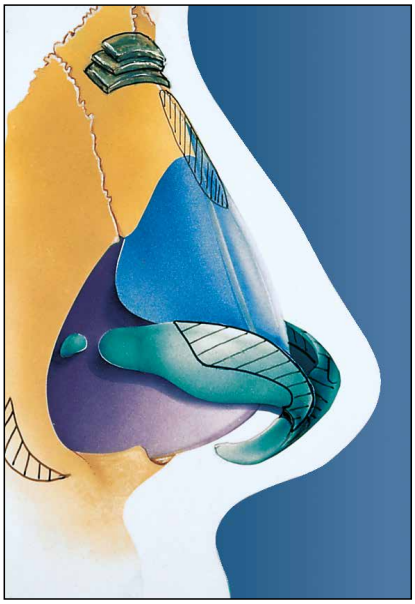
Fig. 27c



Fig. 28a
AIACH **Cartilage Suture Forceps** with teeth and guiding ducts.

Fig. 28b
AIACH **Cartilage Graft Forcpes** with flat slotted jaws.

The graft can be softened or modelled with a *cartilage crusher* (**Fig. 30a**). This instrument allows the cartilage to be crushed to the desired degree. Moderate crushing produces a flat septal fragment which is malleable and has a tile-like appearance (**Fig. 30b**). More vigorous crushing produces cartilage with a quality similar to lace.

By crushing an irregular graft, the surface can be made more even so as to fashion a thinner and more regular fragment for use as a covering graft.

Two or three layers of cartilage grafts can be superimposed using the *cartilage graft forceps* with a slit (**Figs. 28b, 31a, b**), and can be assembled by suturing with a straight needle. These assembled grafts are then tailored to the shape of the hull of a boat by beveling the edges. Sculpturing a dorsal graft should take into account the convex contour of the bony cartilaginous dorsum and variable thickness of the covering soft tissues. The edges of the graft can be crushed with a *crusher* (**Fig. 30a**), and the edges and surface smoothed and beveled with a blade.

Fig. 30a

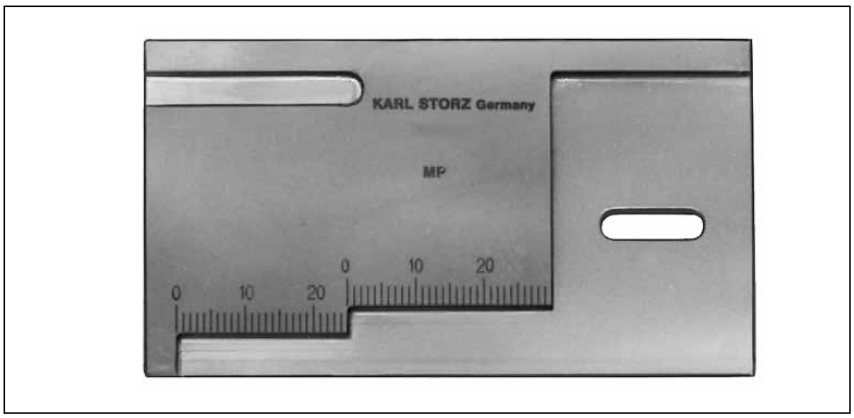

Fig. 29
AIACH **Working Grid** for preparation of cartilage and bone grafts.

Fig. 30b

Fig. 31a

Fig. 31b

Fig. 32a

Insertion of a double-layer dorsal graft. Once the forceps have been placed exactly along the midline, a transcutaneous needle is used to affix the graft while the forceps is removed (**Figs 32a–b**).

Middle Vault

Spreader grafts are easily placed at the anterior border of the septal cartilage to prevent or correct a middle vault collapse. (**Figs 33a–c**).

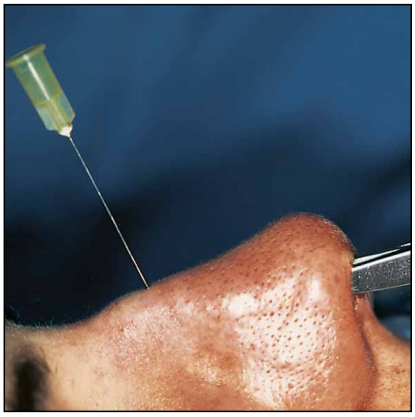

Fig. 32b

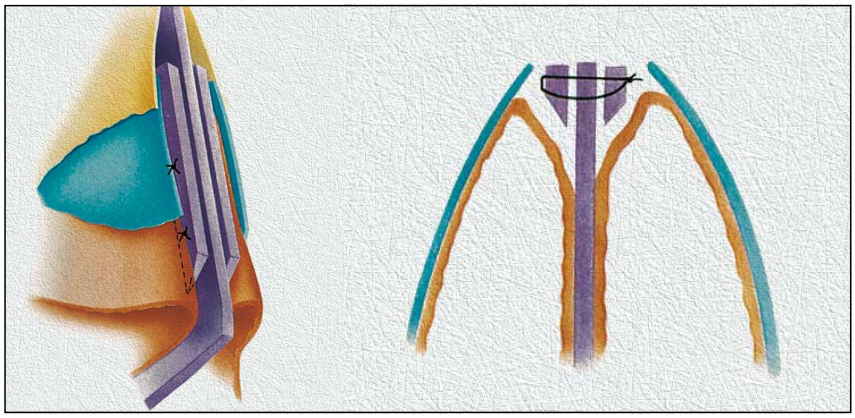

Fig. 33a

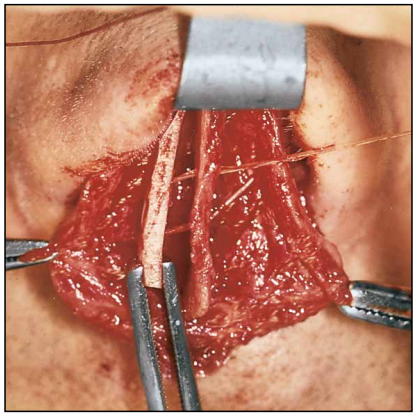

Fig. 33b

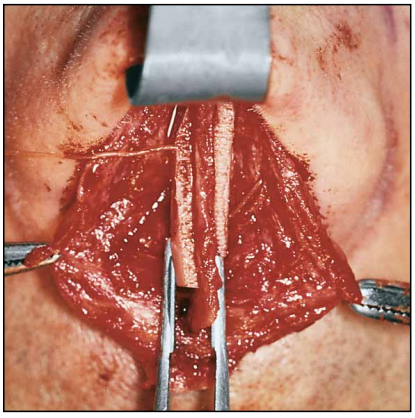

Fig. 33c

Tip and Columella

The objective of nasal tip surgery is to create harmony of contour, position and projection of the nasal tip with the other “volumes” of the nasal pyramid. Cartilage grafts have the advantage of providing simultaneously substantial improvement of nasal tip projection and correction of the contour and definition of the tip lobule.

Choice of Graft Material: septal and conchal cartilages are commonly used in a tip graft, but a part of the nasal hump can also be used in a tip graft provided the hump is resected in one piece.

Choice of Procedure: probably the most suitable procedure is one that permits correction of the projection, definition, and contour of the tip lobule. The type of graft to be used depends on the extent of projection required, medial crural length and support, columella lobular contour, skin condition and size, and condition of the grafting material. In thick-skinned patients, a sufficiently rigid graft is required to resist the pressure exerted by the soft tissues. The bony segment of the hump can be tailored and used as a shield graft. In thin-skinned patients the graft can be slightly crushed (see **Fig. 34b,** p. 18).

Two spreader grafts were placed on either side of the dorsal septal border and fixed with transseptal sutures. Thus, the middle third could be enlarged, providing a better balance with the upper and lower portions of the nose. Two fragments of cartilage were crushed and placed superficially to the upper lateral cartilages.

Fig. 33d+e
Patient presenting with a broad nasal tip and narrow middle vault.

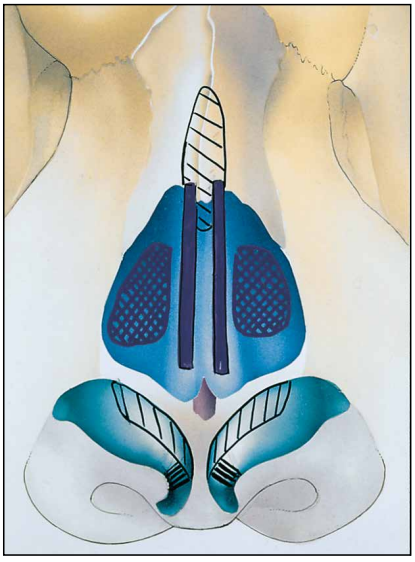

Fig. 33f



Fig. 34a
AIACH Cartilage Suture Forceps for cartilage suture, with teeth and guiding ducts.

Shield graft: placement of a triangular graft (**Fig. 34c**) (Sheen) between the columella lobular junction and the tip-defining points produces an increase in projection as it improves the shape of the lobule; the procedure is delicate and requires extreme care at each stage and a graft of adequate shape and thickness. The base or anterior border of the graft determines the width of the tip lobule, i.e. the interdomal distance.

A *cartilage suture forceps with triangular jaws* allows for easily cutting and fashioning the graft and gently rounding its corners to avoid visible projection under a thin skin and assembling multi-layered grafts (**Fig. 34a**).

Smaller pieces of slightly crushed cartilage can be placed superficially to the main graft to improve the infratip lobule contour. The external approach offers better control of the symmetry of the underlying structures and simpler and more precise positioning of the graft beneath the medial crura. After elevating the columellar flap, the graft can be affixed with several sutures to the adjacent tissue, cartilage, and soft tissue (6/0 PDS).

Fig. 34b
Stiffness of the shield graft is reduced by gentle crushing.

Onlay Graft

Grafts can be stabilized exactly in the desired position by pulling out sutures at the level of the domes. However, an open approach provides for even better control of graft positioning and fixation of single and multilayered grafts. The grafts are then sculptured with accuracy (**Figs. 35a+b**).

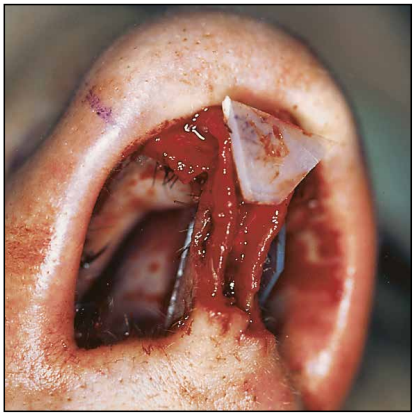

Fig. 34c

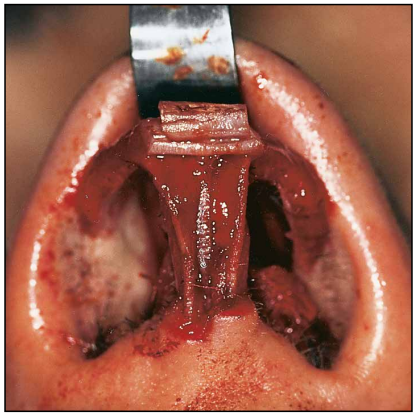

Fig. 35a

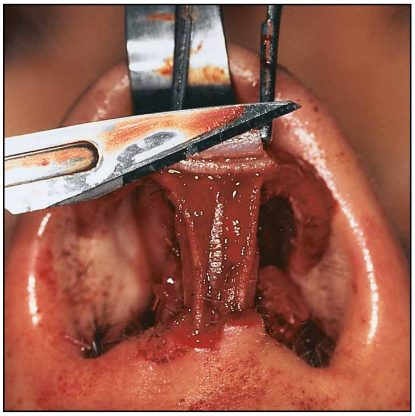

Fig. 35b

Columellar Strut

A columellar strut is fashioned to reinforce or augment the support of the medial crura, and augment the tip projection without modifying the contour of the lobule, and to correct anomalies in the alar-columellar proportion (**Figs. 36 a–b**).

A columellar strut can be placed between the medial crura. Loss in tip projection can be prevented by extending the strut to the premaxilla. It is also feasible to lengthen the medial support by pushing the strut towards the premaxilla while the medial crura are advanced anteriorly on the strut to provide the desired degree of projection. Subsequently, this construction is fixed with transcolumellar sutures. A columellar strut can also be placed in the membranous septum in order to improve the alar-columellar proportion.

The optimal grafting material to use is septal cartilage since it is flat, easy to harvest, and well-suited for this type of grafting; however, alternative materials include costal and conchal cartilage as well as cortical bone.

The columellar strut should be thicker posteriorly, so that it rests readily/well on the nasal spine without lateral displacement. When the naso-labial angle is acute, triangular septal grafts with a thick base resting well on the nasal spine are often associated with anterior triangular shortening.

The columellar strut is very useful and can be utilized in conjunction with onlay or shield grafts.

With an endonasal approach, a columellar strut can be introduced through a marginal incision anterior to the columellar-lobular junction. The dissection is carried out between the crura or in the membranous septum depending on the desired effect. The transcolumellar approach permits easier and more precise insertion of a columellar strut. A short sagittal mid-columellar incision can also be used in the infratip segment, permitting rapid and precise placement of the graft with a nearly invisible scar of only 4 millimeters in length.

A **premaxillar graft** (bone or cartilage) or a graft placed under the base of the columella is indicated to correct premaxillary hypoplasia or a retrusive alar base.

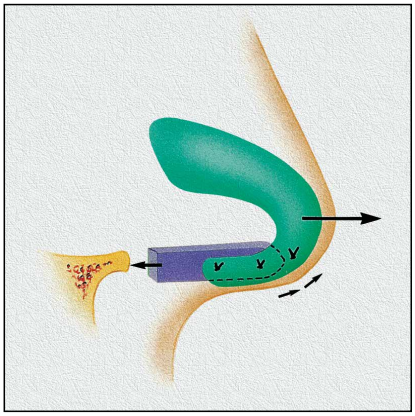

Fig. 36a

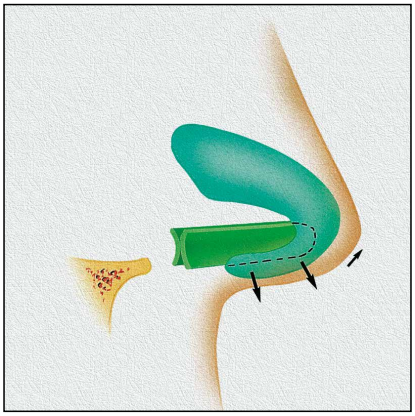

Fig. 36b

Fig. 37a

Fig. 37b

Fig. 37c

Alar Graft

The lateral crura can be reconstructed or reinforced by slicing off a thick fragment of septal or costal cartilage.

For this purpose, the cartilage fragment is placed in the area of the working grid with a depth of 0.5 mm (**a**), firmly pressed down with a thumb, and sliced with a no. 11 blade (**b**). Thus, two 0.5 mm thick fragments are obtained which fit very nicely for alar reconstruction (**c**) (**Figs. 37a–c**).

Grafting techniques are quite common in rhinoplasty. Various areas of the nose can be grafted, if required. Grafting techniques require adequate graft specimens and careful preparation and fixation.

Fig. 38a
Patient presenting with a projecting nose, high tip projection and exposed columella (**Figs. 38e+f,** see continuation on opposite page).

Nasal tip projection was corrected by dissecting the middle crura and overlapping the cartilages (see **Fig. 13,** page 8).

Preoperative (**e**) and postoperative (**f**) view.

Secondary correction of a cleft-lip nose presenting with a low radix of a moderate cartilaginous hump and, most notably, an asymmetric tip lobule and flared nostrils (**Figs. 39 a–e**).

Septal cartilage was harvested for grafting to the upper dorsum, the tip (double layer), the columella, and the left ala.

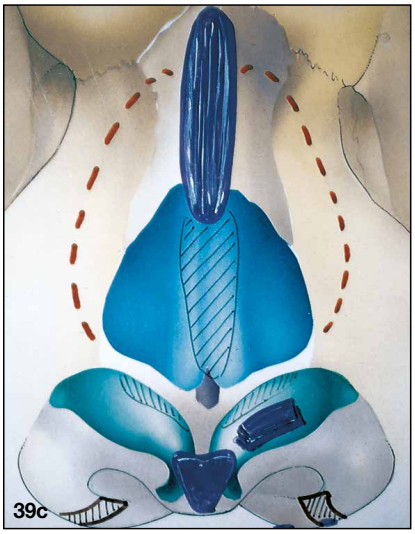

Fig. 39 d
The remaining fragments of septal cartilage were placed at the base of the left ala using an intra-oral approach.

Fig. 39 e
The alar base was resected (3 millimeters) and the base of the left ala advanced. The patient's upper lip scar was corrected.

Instruments for Rhinoplasty

Nasal Specula, Hooks and Elevators

400600

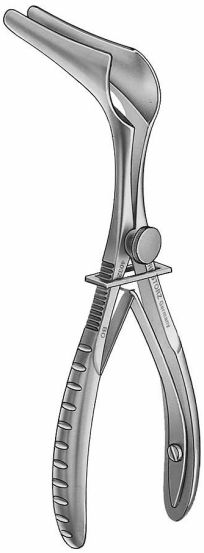

403290

403855

499001

499202
499205
499210

499202–
499210

475000

474000

478000

479408

479000

400600	HARTMANN **Nasal Speculum,** for children, length 13 cm
403290	KILLIAN-STRUYCKEN **Nasal Speculum,** with set rack, blade length 90 mm, length 15 cm
403855	COTTLE **Nasal Speculum,** with set screw, blade length 55 mm, length 13 cm
499001	KILNER-GILLIES **Hook,** one prong, small curve, length 17 cm
499202	JOSEPH **Double Hook**, sharp, width 2 mm, length 15 cm
499205	**Same,** width 5 mm
499210	**Same,** width 10 mm
475000	KILLIAN **Elevator,** double-ended, standard model, shovel-shaped blades, sharp and blunt, length 18 cm
474000	FREER **Elevator,** double-ended, semisharp and blunt, length 20 cm
478000	JOSEPH **Elevator,** slightly curved, length 17.5 cm
479408	COTTLE **Elevator,** slightly curved, width 8 mm, length 19.5 cm
479000	MASING **Elevator,** double-ended, graduated, sharp and blunt, length 22.5 cm

Instruments for Rhinoplasty
Chisels, Mallet, Rongeur and Hone

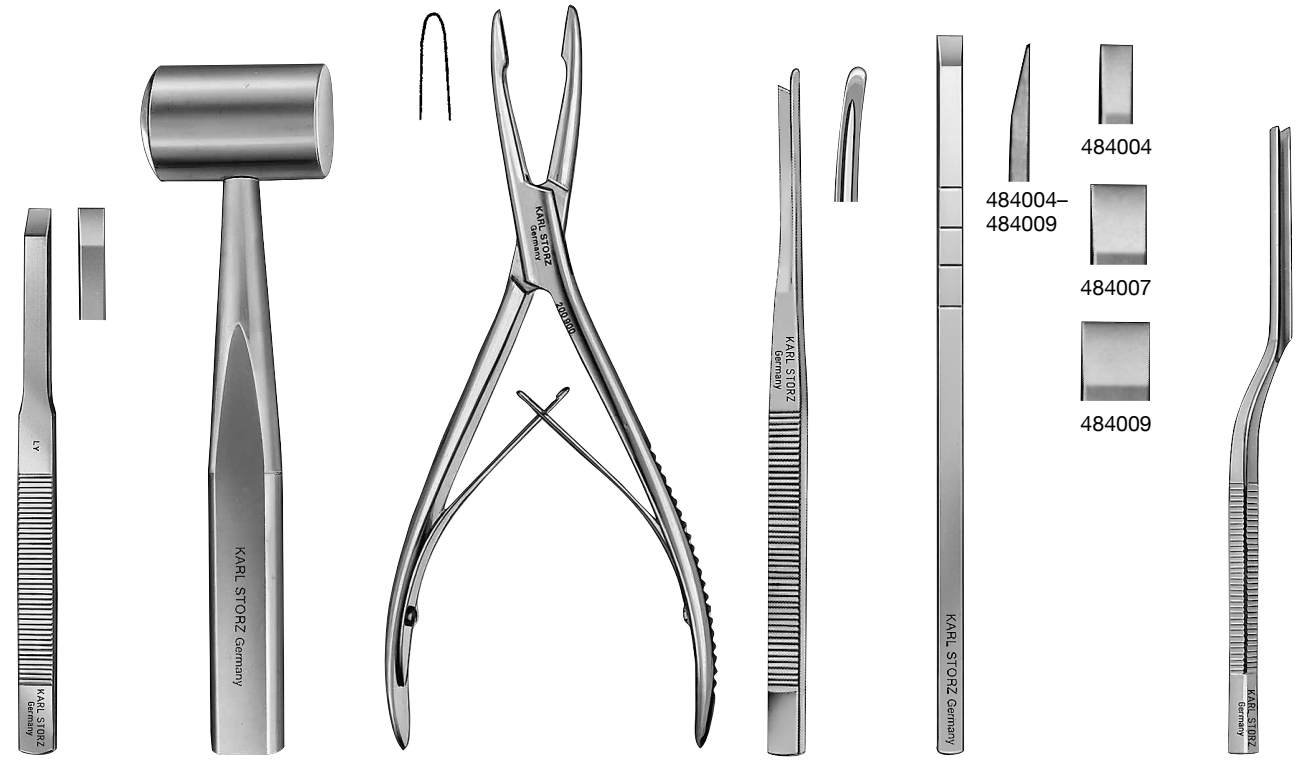

170602	TRAUTMANN **Mastoid Chisel,** width 2 mm, length 14 cm
174200	COTTLE **Mallet,** length 18 cm
200900	HEANLEY **Rongeur,** straight, length 19 cm
484600	MASING **Chisel,** slightly curved, with rounded guard right side, length 18 cm
484700	**Same,** on left side
484004	COTTLE **Chisel,** flat, graduated, straight, width 4 mm, length 18.5 cm
484007	**Same,** width 7 mm
484009	**Same,** width 9 mm
480000	KILLIAN-CLAUS **Septum Chisel,** V-shaped cutting edge, length 16.5 cm

Instruments for Rhinoplasty

Scissors, Dressing and Tissue Forceps, Nasal Rasps
Narrow Rasp and Tenon Mortise Rasp

513200	WALTER **Scissors,** angled, length 10 cm
511010DS*	**Scissors,** extra delicate, straight, sharp/sharp, length 10 cm, color code: one gold-plated handle ring
511210DS*	**Same,** curved
512614	METZENBAUM **Scissors,** with tungsten carbide inserts, curved, length 14 cm
513700DS*	FOMON **Scissors,** curved surface, slender, working length 6.5 cm, color code: one gold-plated handle ring
513512	**Scissors,** straight, length 12 cm
533012	ADSON **Dressing Forceps,** serrated, length 12 cm
533212	ADSON-BROWN **Tissue Forceps,** atraumatic, fine side grasping teeth, length 12 cm
523812	**Nasal Rasp,** tungsten carbide, double-ended, rasp blades Fig. 1 and 2, coarse, length 20.5 cm
523878	**Same,** rasp blades Fig. 7 and 8, medium and fine
523891	**Same,** rasp blades Fig. 9 and 10, fine
498815	AIACH **Narrow Rasp,** double-ended, medium, width 5 mm and 3 mm, length 20 cm
498816	AIACH **Tenon Mortise Rasp,** double-ended, medium, one side with augmented teeth, other side slotted, without teeth, length 20 cm

Please note:
*) Diamond Standard Scissors – with Ultimate Cutting Quality.

Instruments for Rhinoplasty

Retractors, Forceps, Osteotome for Hump Removal with Guiding Rod



498801

498803

498804

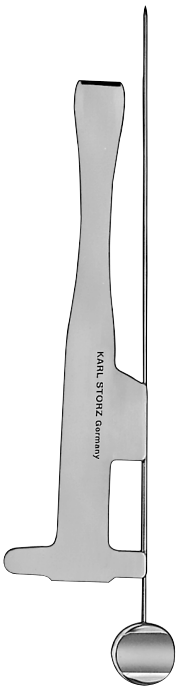

498809-
498810

498801	AIACH **Nasal Retractor,** double-ended, blades 20 mm and 30 mm, with perforations for use with self-retaining forceps 498804, length 11 cm
498803	AIACH **Nasal Retractor,** double-ended, S-shaped, with perforations for use with self-retaining forceps 498804, length 13 cm
498804	AIACH **Self-retaining Forceps,** curved, length 16 cm, for use with nasal retractor 498801 / 498803
498809	AIACH O**steotome for Hump Removal,** with lateral guiding rod, width 10 mm
498810	**Same,** width 13 mm
498810F	**Guiding Rod,** for 498809 / 498810, only

Instruments for Rhinoplasty

Instruments for Cartilage Grafting

498824

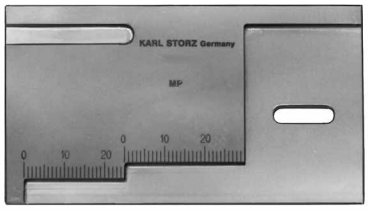

498820

498826

498822

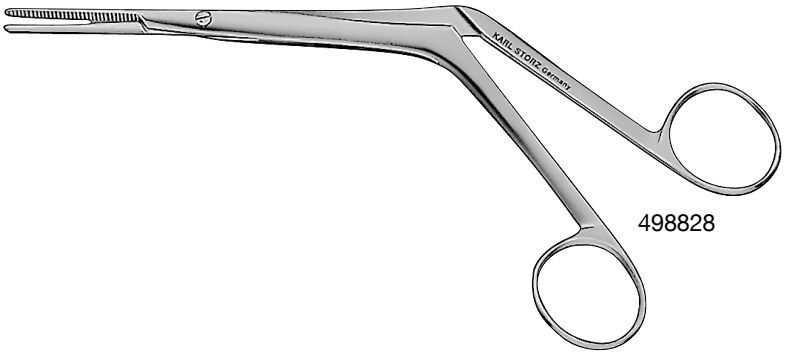

498828

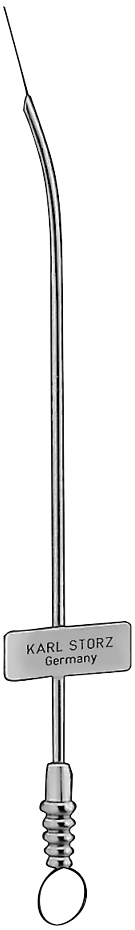

498832

498820	AIACH **Grid,** for preparation of cartilage and bone grafts, graduated, size 90 x 50 mm
498822	AIACH **Cartilage Graft Forceps,** for grasping and preparation of cartilage and bone grafts, with slotted jaws, length 15 cm
498824	AIACH **Cartilage Crusher,** crusher size 50 x 30 mm
498826	AIACH **Cartilage Suture Forceps,** for cartilage suture, with teeth, triangular-shaped, with guiding slits, length 10 cm
498828	AIACH **Septal Material Harvesting Forceps,** angled, strong, length 12 cm
498832	AIACH **Suction Elevator,** distal end slightly curved, with stylet, length 18 cm

Headlight KS60™, Cold Light Fountain XENON NOVA® 175 and Mobile Stand

310060

310060 **Headlight KS60™,** with double lens system and Y-fiber optic light cable, >175,000 lux, illuminated area adjustable from 20 – 80 mm in diameter with 40 cm working distance,

consisting of:

310063 **Headlight KS60™,** with removeable and sterilizable Focus Handle 310065

310070 **Headband,** fully adjustable, with Forehead Cushion 078511, with cross band, including holder for Headlight 310060/310063

495NY **Y-Fiber Optic Light Cable,** with special protective casing for Headlight 310063, length 290 cm

078681 **Clip with Band,** for attaching the fiber optic light cable to OR clothing

20131501 **Cold Light Fountain XENON NOVA® 175**
power supply: 100 – 125/220 – 240 VAC, 50/60 Hz
consisting of:

20131520 **Cold Light Fountain XENON NOVA® 175**

400A **Mains Cord**

20132026 **Spare Lamp,** 175 watt, 15 volt

20020023 **Mobile Stand,** height-adjustable, rides on 5 antistatic casters, 2 equipped with locking brakes, tray made of V2A, plastic-coated, for use with cold light fountains, insufflator, pump and motor systems
Dimensions:
Tray: 330 mm x 330 mm (w x h)
working height: 900 mm – 1500 mm

20020033 **Holder** for Headlight

with the compliments of

KARL STORZ — ENDOSKOPE